

# DISTRACTION OSTEOGENESIS IN PATIENTS WITH CRANIOFACIAL ANOMALIES

## OSTEOGÊNESE POR DISTRAÇÃO EM PACIENTES COM ANOMALIAS CRANIOFACIAIS

CAIO SILVA LINDOSO<sup>1\*</sup>, FLAYLLA ANIELLY ALVES DA SILVA<sup>2</sup>, BIANCA MAFRA LIMA FRANÇA ARAÚJO<sup>3</sup>, LARISSA SILVA LINDOSO<sup>4</sup>, KAUÊ SILVA LINDOSO<sup>5</sup>, LIVIA ONILDE LINDOSO MARQUES<sup>6</sup>, ANNE CAROLINE DOS SANTOS FONSECA<sup>7</sup>, ANA CARLA SOUZA COSTA<sup>8</sup>

1. Undergraduate Dental Student, Estácio College, São Luís, MA, Brazil; 2. Resident of Oral and Maxillofacial Surgery, Faculty of Sciences of Tocantins, Araguaína, TO, Brazil; 3. Resident of Oral and Maxillofacial Surgery, Faculty of Sciences of Tocantins, Araguaína, TO, Brazil; 4. Dentist, Edufor College, São Luís, MA, Brazil; 5. Undergraduate Dental Student, Estácio, São Luís, MA, Brazil; 6. Undergraduate Dental Student, Estácio College, São Luís, MA, Brazil; 7. Undergraduate Dental Student, Estácio College, São Luís, MA, Brazil; 8. Doctor in Orthodontics, Estácio College, São Luís, MA, Brazil.

\*São Luís Rei de França Avenue, São Luís, Maranhão, Brazil. ZIP-CODE: 65065-470. [meccaioslindoso@gmail.com](mailto:meccaioslindoso@gmail.com)

Received: 15/05/2026. Accepted: 29/05/2026

### ABSTRACT

Distraction osteogenesis (DO) is a surgical technique that promotes bone formation through the gradual separation of bone segments following osteotomy and is widely used in the treatment of craniofacial anomalies. This study aimed to describe the application of DO in these patients, addressing its biological basis, indications, limitations, and clinical outcomes. This is a literature review conducted using PubMed, Scielo, and the Virtual Health Library (BVS) databases, including studies published between 2021 and 2026 in English and Portuguese. The findings indicate that DO involves not only a mechanical process but also complex biological mechanisms, such as mechanotransduction and activation of molecular pathways related to osteogenesis. The technique enables the formation of vascularized bone, progressive adaptation of soft tissues, and lower relapse rates compared to conventional approaches. However, its success depends on individualized planning, proper control of the activation protocol, and patient compliance, in addition to potential complications. It can be concluded that DO is an effective and integrated therapeutic approach, providing significant functional and aesthetic benefits in the treatment of craniofacial deformities.

**KEYWORDS:** Osteogenesis, Distraction; Craniofacial Abnormalities; Bone Lengthening.

### RESUMO

A osteogênese por distração (OD) é uma técnica cirúrgica que promove a formação óssea através da separação gradual de segmentos ósseos após osteotomia, sendo amplamente utilizada no tratamento de anomalias craniofaciais. Este estudo teve como objetivo descrever a aplicação da OD nesses pacientes, abordando seus fundamentos biológicos, indicações, limitações e resultados clínicos. Trata-se de uma revisão da literatura realizada nas bases de dados PubMed, SciELO e Biblioteca Virtual em Saúde (BVS), incluindo estudos publicados entre 2021 e 2026 em inglês e português. Os resultados indicam que a OD envolve não apenas um processo mecânico, mas também mecanismos biológicos complexos, como mecanotransdução e ativação de vias moleculares relacionadas à osteogênese. A técnica possibilita

a formação de osso vascularizado, adaptação progressiva dos tecidos moles e menores taxas de recidiva em comparação com as abordagens convencionais. Contudo, seu sucesso depende do planejamento individualizado, do controle adequado do protocolo de ativação e da adesão do paciente, além de potenciais complicações. Conclui-se que a OD é uma abordagem terapêutica eficaz e integrada, proporcionando benefícios funcionais e estéticos significativos no tratamento de deformidades craniofaciais.

**PALAVRAS-CHAVES:** Osteogênese por distração; anomalias craniofaciais; alongamento ósseo.

### 1. INTRODUCTION

Distraction Osteogenesis (DO) is a surgical technique that promotes bone formation by gradually separating two segments after an osteotomy. It was first refined by Ilizarov in the 1950s in orthopedics, with the introduction of external fixation devices and the establishment of optimal lengthening protocols. The clinical consolidation of this technique in Oral and Maxillofacial Surgery occurred in 1992, when McCarthy and colleagues performed mandibular distraction in a patient with hemifacial microsomia, integrating DO into the treatment of craniofacial deformities<sup>1</sup>.

The technique is based on the gradual elongation of the fibrous callus formed after osteotomy, which, when adequately stabilized, develops into mature bone. The process is divided into three phases: latency, activation, and consolidation. During the activation phase, gradual distraction is performed at a rate of approximately 1 mm per day, with stabilization achieved using distraction devices. Among its main advantages, DO promotes the formation of well-vascularized and resistant bone, presents lower relapse rates compared with conventional grafts, and allows adaptation of the surrounding soft tissues, including skin, muscles, mucosa, blood vessels, and nerves<sup>2</sup>.

In terms of surgical techniques, there are external devices, such as the RED frame, which allow postoperative modulation of the vector in maxillary and midfacial advancements, although they may cause discomfort and aesthetic concerns<sup>3</sup>. Internal devices, fixed directly to the bone, are used in mandibular distraction osteogenesis (MDO), maxillary anterior segmental distraction osteogenesis (MASDO), and posterior cranial vault distraction osteogenesis (PVDO), offering greater comfort and improved aesthetics, but with more limited adjustability. Hybrid systems, in turn, combine the advantages of both approaches and are indicated for more complex midfacial cases that require precise vector control<sup>4</sup>.

Thus, it is widely used in cases of facial asymmetries, mandibular deficiencies, and other deformities associated with craniofacial syndromes. It is indicated for congenital anomalies, such as cleft lip and palate and micrognathia, allowing correction of both functional and aesthetic impairments<sup>5</sup>. In patients with severe airway obstruction, as commonly seen in individuals with Pierre Robin sequence, distraction osteogenesis may represent an effective alternative to tracheostomy, promoting adequate bone growth and adaptation of the surrounding soft tissues. Furthermore, the technique is also applied in other syndromes, such as Treacher Collins, Crouzon, and Apert<sup>6</sup>.

Therefore, understanding the biological principles, indications, limitations, and clinical outcomes of this technique is essential for Oral and Maxillofacial Surgeons and the multidisciplinary team, enabling more precise, safe, and functional interventions. Accordingly, the aim of this study is to describe the application of distraction osteogenesis in the treatment of patients with craniofacial anomalies, evaluating its biological foundations, indications, limitations, and clinical outcomes.

## 2. MATERIAL AND METHODS

This study is a literature review including systematic reviews, meta-analyses, retrospective studies, and case reports published between 2021 and 2026. The search was conducted in the PubMed, SciELO, and Virtual Health Library (BVS) Regional Portal databases, including articles published in Portuguese and English. The search strategy used the keywords “Osteogenesis, Distraction,” “Craniofacial Abnormalities,” and “Bone Lengthening,” as well as MeSH terms, combined using Boolean operators (AND/OR) to refine the results. Studies were selected based on their relevance to the topic, focusing on the relationship between distraction osteogenesis techniques and craniofacial abnormalities.

A total of 425 articles were initially identified. After the removal of 65 duplicates, 360 articles remained for screening based on title and abstract. At this stage, 45 *in vitro* studies, 38 animal studies, 120 unrelated articles, and 95 studies outside the scope of the research were excluded. Subsequently, 62 articles were selected for full-text assessment. Of these, 12 were

excluded due to methodological issues, 9 due to inadequate population, 9 due to insufficient data, and 10 due to the absence of clinical data. Ultimately, 22 articles were included in the literature review.

## 3. LITERATURE REVIEW

Distraction osteogenesis (DO) is a surgical technique that enables new bone formation through the controlled application of tensile forces to a previously osteotomized bone segment. The fundamental biological principle underlying this technique is the tension–stress effect, whereby gradually applied mechanical forces stimulate bone regeneration, accompanied by angiogenesis and the formation of supporting soft tissues<sup>7</sup>.

Furthermore, the regenerative response depends on the integrity of the periosteum and local vascularization. In the craniofacial region, bone formation occurs predominantly through intramembranous ossification, which contributes to more predictable outcomes. At the cellular level, DO induces a regenerative microenvironment characterized by osteoblastic differentiation, extracellular matrix deposition, and progressive bone remodeling<sup>8</sup>.

Control of the distraction vector is one of the most critical factors for treatment success. The direction of traction may be horizontal, vertical, oblique, or three-dimensional, depending on the deformity being corrected. In mandibular hypoplasia, for example, distraction is typically performed in the anteroposterior (horizontal) direction, whereas maxillary deficiencies may require a combination of vectors to restore both projection and facial height (Figure 1). Studies involving virtual surgical planning have demonstrated that three-dimensional (3D) software allows accurate simulation and adjustment of the distraction vector, reducing asymmetries and postoperative complications. Therefore, digital technologies have become the gold standard in craniofacial DO planning<sup>9</sup>.

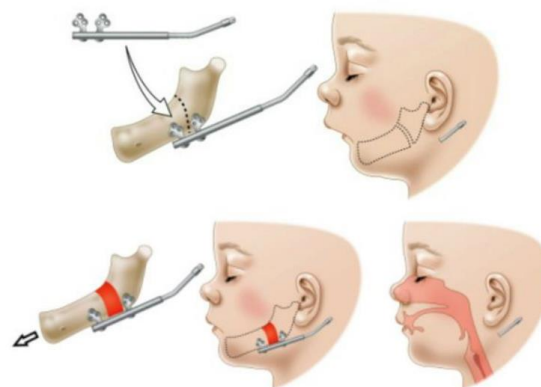


Figure 1. Mandibular distraction osteogenesis<sup>22</sup>.

Following the latency period, typically lasting 5 to 7 days, the activation phase begins, during which the device is progressively adjusted to promote bone elongation. The classical protocol recommends a distraction rate of approximately 1 mm per day, divided into increments of 0.25 mm every 6 hours. This rate is

based on experimental studies demonstrating an optimal balance between mechanical stimulation and tissue viability. Accelerated rates may impair osteogenesis, leading to fibrosis or pseudoarthrosis, whereas excessively slow activation may result in premature consolidation and resistance to elongation<sup>10</sup>.

Several factors directly influence the success of DO, including patient age, local vascularization, mechanical stability of the device, and vector control. Children and young patients exhibit greater osteogenic and regenerative capacity, resulting in faster and denser bone formation, with the best outcomes typically observed between 5 and 10 years of age. Adequate vascularization is essential to ensure the supply of nutrients and progenitor cells to the distraction site. In addition, mechanical stability of the fixation device is crucial: excessive micromovements may compromise callus formation, while excessive rigidity may inhibit proper remodeling. Finally, precise three-dimensional vector control ensures that bone elongation occurs in the planned direction, preventing secondary deformities<sup>11</sup>.

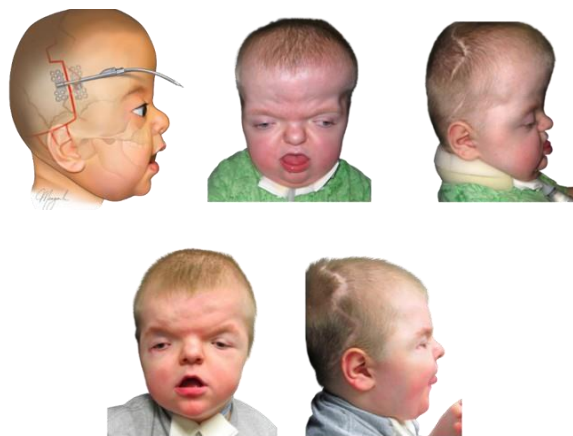Despite its effectiveness, DO is not free of complications. The most commonly reported include pin-site infection, vector misalignment, fibrosis, pseudoarthrosis, bone relapse, and transient neurosensory disturbances. Complication rates range from 15% to 30%, with infections and mechanical failures being the most prevalent. Technical factors, such as improper device positioning, inadequate activation, and poor planning, are directly associated with unfavorable outcomes<sup>12</sup>.

Distraction osteogenesis currently represents one of the main therapeutic strategies for correcting complex craniofacial deformities, especially those involving three-dimensional bone deficiency and limitations for conventional advancements. Its main advantage is promoting gradual and physiological bone growth, with simultaneous regeneration of soft tissues, avoiding secondary grafts and minimizing relapse. The technique is based on the adaptive capacity of the craniofacial skeleton, whose intramembranous ossification and high vascularization favor an efficient osteogenic response, even in pediatric patients and in regions with delicate anatomy<sup>13</sup>.

Distraction osteogenesis (DO) is indicated in cases of congenital or acquired bone hypoplasia, deformities resulting from craniofacial syndromes, and maxillomandibular deficiencies associated with cleft lip and palate. The technique shows predictable results in young patients by leveraging osteogenic potential and the facial remodeling capacity during development. Additionally, early application can prevent more invasive surgical interventions and reduce respiratory and functional complications<sup>14</sup>.

In syndromic craniofacial dysplasias, such as Crouzon and Apert syndromes (Figure 2), DO plays an essential role in correcting midfacial hypoplasia and orbital retrusion, which are often associated with exophthalmos and airway obstruction, demonstrating

that transsutural distraction allows gradual maxillary advancement and significant improvement in the upper airway, with lower morbidity compared to traditional Le Fort III osteotomies<sup>13</sup>.



**Figure 2.** PVDO sequence with coronal incision, osteotomy, and internal device<sup>23</sup>.

In cases of hemifacial microsomia, mandibular distraction osteogenesis has become one of the most effective approaches to restore facial symmetry and correct skeletal discrepancies. The technique promotes not only bone lengthening but also favorable adaptations in adjacent soft tissues, including the masseter muscle, contributing to more balanced functional and aesthetic outcomes. It enables better mandibular projection, occlusal correction, and reduction of asymmetries. Furthermore, the use of digital methods enhances surgical predictability and allows individualized treatment according to the degree of hypoplasia presented by each patient<sup>15</sup>.

In Pierre Robin sequence, the main indication for DO is the treatment of severe micrognathia associated with neonatal airway obstruction. The technique is effective in relieving airway obstruction and reducing the need for tracheostomy, with acceptable complication rates. Despite technical challenges, early distraction has proven to be a safe and effective alternative for functional airway management<sup>16</sup>.

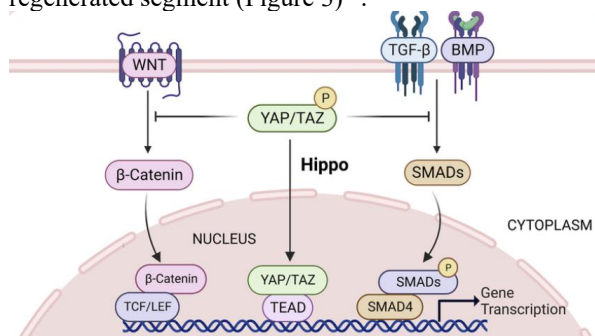
Surgical planning is a critical step for the success of distraction. It involves detailed cephalometric analysis, 3D tomography, and ideally computer-assisted virtual planning. Digital simulation allows for the definition of traction vectors, angulations, and optimal device positioning, minimizing intraoperative errors and ensuring aesthetic and functional predictability<sup>9</sup>.

The surgical procedure follows classic phases: osteotomy, device placement, latency, activation, and consolidation. After osteotomy under aseptic conditions, the distractor is stably fixed and aligned with the planned vector. Following a latency period of 5 to 7 days, activation begins at an average rate of 1 mm/day until the desired lengthening is achieved. Bone consolidation occurs on average between 6 to 8 weeks, depending on age and anatomical site<sup>17</sup>.

During the distraction period, clinical and radiographic follow-up is essential to assess bone

callus quality, vector alignment, and patient adaptation. Strict pin hygiene and infection prevention are crucial, especially with external devices. Most complications can be avoided with proper vector control and maintenance of mechanical stability<sup>16</sup>.

The application of distraction osteogenesis strongly stimulates bone tissues through the so-called distraction “gap,” in which, after osteotomy, a fibrous callus forms and is progressively stretched and mineralized. During the activation phase, mechanotransduction pathways such as the Wnt/ $\beta$ -catenin signaling pathway, TGF- $\beta$ /BMP signaling pathway, and Hippo signaling pathway are activated, facilitating the differentiation of skeletal stem cells into osteoblasts and the formation of new capillaries in the regenerated segment (Figure 3)<sup>18</sup>.



**Figure 3.** Hippo activation sequesters YAP/TAZ, inhibiting Wnt/ $\beta$ -catenin and TGF- $\beta$  signaling<sup>24</sup>.

Vascularization is fundamental: experiments involving the administration of bone morphogenetic protein 2 (BMP-2) and vascular endothelial growth factor (VEGF) have demonstrated increased trabecular volume and vascular density in the distraction gap, reinforcing the critical role of angiogenesis in bone regeneration<sup>19</sup>.

Bone regeneration during DO occurs predominantly through intramembranous ossification, especially in the craniofacial skeleton, although aspects of endochondral ossification may occur in certain defect contexts or under prolonged mechanical loading. The intramembranous pathway promotes faster bone formation with less intermediate cartilage, which is advantageous in craniofacial DO. Understanding these biological processes provides a theoretical basis for DO application: ensuring adequate latency, appropriate activation rate, and sufficient vascular support favors effective ossification and reduces the risk of relapse or premature consolidation<sup>20</sup>.

In patients with mandibular or midfacial hypoplasia resulting from craniofacial anomalies (such as Pierre Robin sequence, hemifacial microsomia, or cleft lip and palate sequelae), distraction osteogenesis demonstrates functional improvement and significant aesthetic effects. For example, children with Pierre Robin sequence undergoing mandibular DO show increased upper airway volume and improved apnea/hypopnea indices, directly impacting breathing and, consequently, quality of life<sup>21</sup>.

Additionally, by correcting bone positioning and

allowing gradual adaptation of soft tissues, the technique promotes facial symmetry and aesthetic harmony, improving patients' self-image and reducing the psychosocial impact associated with craniofacial deformities<sup>22</sup>.

#### 4. DISCUSSION

Distraction osteogenesis (DO) has consolidated itself as an approach that goes beyond the purely mechanical concept of bone lengthening by integrating complex biological phenomena that support its clinical predictability<sup>9</sup>. The tension–stress principle not only explains new bone formation but also demonstrates that the quality of the regenerated tissue depends on the interaction between mechanical stimulus and the local cellular response<sup>7</sup>.

In this context, DO differs from other reconstructive approaches by inducing a biologically active environment in which angiogenesis and osteogenesis occur simultaneously and in an integrated manner, suggesting that the success of the procedure is more closely related to the proper modulation of this microenvironment than to technical execution alone<sup>8, 11</sup>.

From a biomechanical standpoint, control of the distraction vector emerges as one of the main determinants of therapeutic outcomes, especially in complex craniofacial deformities. Although three-dimensional planning has been described as the gold standard, its real contribution goes beyond geometric precision, directly influencing functional stability and aesthetic outcomes<sup>9, 10</sup>.

This reinforces the idea that clinical failures often attributed to the method may, in reality, be related to limitations in planning or vector execution, highlighting the need for integration between anatomical knowledge, digital technology, and surgical expertise<sup>11, 14</sup>.

The activation protocol, whose classical standardization (1 mm/day) should be interpreted on an individualized basis. Although this rate represents an appropriate balance between osteogenic stimulation and tissue viability, factors such as age, vascularization, and type of deformity may modify the biological response<sup>10</sup>. Younger patients exhibit greater regenerative potential, which may justify protocol adjustments, while unfavorable local conditions require greater caution to avoid complications such as fibrosis or pseudoarthrosis<sup>11</sup>.

When applied to craniofacial anomalies, DO demonstrates a paradigm shift in the treatment of these conditions by prioritizing progressive tissue adaptation rather than abrupt corrections. Its ability to promote bone growth alongside soft tissue accommodation reduces tension and, consequently, the likelihood of relapse, representing an important advantage over conventional osteotomies. However, this same characteristic implies a longer treatment duration and greater dependence on patient compliance<sup>13, 14</sup>.

This feature is particularly relevant in syndromes such as Crouzon and Apert, in which the simultaneous

correction of bony structures and airway represents a therapeutic challenge. The possibility of early intervention expands the clinical impact of the technique, not only in facial aesthetics but also in preventing functional complications such as respiratory disorders, reinforcing its role as not only a reconstructive but also a functional approach<sup>13,16</sup>.

Furthermore, in conditions such as hemifacial microsomia and Pierre Robin sequence, DO stands out for its ability to significantly improve respiratory function and facial symmetry. Evidence shows that progressive mandibular advancement can reduce the need for more invasive interventions, such as tracheostomy, indicating a direct benefit in patient morbidity. From this perspective, the method should not be evaluated solely by morphological parameters but also by its systemic impacts and effects on quality of life, expanding the traditional criteria for surgical success<sup>12,16</sup>.

The influence of scar-related aspects on the final outcome of distraction osteogenesis. Unlike reconstructions with grafts, in which scar tissue often represents a limiting factor, in DO this tissue is continuously remodeled under mechanical stimulation<sup>20</sup>. However, in patients with a history of unfavorable healing, such as those who have undergone multiple previous surgical interventions, this process may be impaired, negatively affecting regeneration. Therefore, the quality of the recipient bed should be considered not only as an initial factor but as a dynamic element throughout the entire distraction period<sup>18</sup>.

From a biological perspective, the mechanotransduction mechanisms involved in DO reinforce the complexity of bone regeneration. The activation of pathways such as Wnt/ $\beta$ -catenin, TGF- $\beta$ /BMP, and Hippo demonstrates that mechanical stimulation triggers highly regulated molecular responses that are essential for bone and vascular formation. In this sense, it is suggested that future therapeutic approaches may enhance DO outcomes through adjuvant interventions, such as the use of growth factors, paving the way for more advanced tissue engineering strategies<sup>18,19</sup>.

From a broader perspective, DO has evolved from a reconstructive procedure into an integrated approach within a multidisciplinary treatment plan. The involvement of orthodontists, speech therapists, and other healthcare professionals expands the scope of outcomes, enabling not only structural correction but also complete functional rehabilitation of the patient. This integration is particularly relevant in individuals with craniofacial anomalies, in whom multiple systems are involved<sup>13,14</sup>.

Despite its benefits, the complication rate remains a significant clinical challenge. The occurrence of infections, mechanical failures, and vector deviations highlights that the success of DO depends on multiple interdependent factors. In this context, rigorous follow-up throughout all phases of treatment becomes

essential, not only for early identification of complications but also for dynamic adjustments during the distraction process. Thus, DO should be understood as continuous treatment rather than an isolated surgical event<sup>12,16</sup>.

## 5. CONCLUSION

Thus, distraction osteogenesis is established as an integrated approach that goes beyond simple bone lengthening by simultaneously promoting soft tissue adaptation and more stable outcomes in the treatment of craniofacial deformities. Its success is directly related to individualized planning, proper control of the distraction vector, and an understanding of the biological aspects involved in the regenerative process. Although it offers significant functional and aesthetic benefits, its management requires continuous follow-up and a multidisciplinary approach, reinforcing its role as a comprehensive therapeutic strategy with a direct impact on patients' quality of life.

## 6. REFERENCES

- [1] Brody-Camp S, Winters R. Craniofacial distraction osteogenesis. In: StatPearls. Treasure Island (FL): StatPearls Publishing. 2023.
- [2] Burns HR, Wang DS, Abu-Ghnam A, Dempsey RF. Craniofacial distraction osteogenesis. *Semin Plast Surg.* 2023.
- [3] Pandey S, Reddy GS, Chug A, Dixit A. Posterior cranial vault distraction osteogenesis: a systematic review. *J Oral Biol Craniofac Res.* 2022.
- [4] Rickart AJ, Van de Lande LS, O'Sullivan E, Bloch K, Arnaud E, Schievano S, Jeelani NUO, Paternoster G, Khonsari R, Dunaway DJ. Comparison of internal and external distraction in frontofacial monobloc advancement: a three-dimensional quantification. *Plast Reconstr Surg.* 2023.
- [5] Leite RS, Soares ASS, Ramos AN, Amaral DN. Expansão mandibular por distração osteogênica como opção de tratamento interdisciplinar: revisão de literatura. *Braz J Dev.* 2021.
- [6] Thom DH, Lam VN, Son TT. The impact of mandibular distraction osteogenesis on cephalometric measurements in infants with Pierre Robin sequence. *Kobe J Med Sci.* 2023.
- [7] Shah HN, Jones RE, Borrelli MR, Robertson K, Salhotra A, Wan DC, Longaker MT. Craniofacial and long bone development in the context of distraction osteogenesis. *Plast Reconstr Surg.* 2021.
- [8] Mengying J, An Y, Wang Z, et al. Distraction force promotes osteogenic differentiation of Gli1+ cells in facial sutures through primary cilia-mediated Hedgehog signaling pathway. *Stem Cell Res Ther.* 2024.
- [9] Almeida JCC, Grillo R, Teixeira RG. Virtual planning bone distraction as a golden standard in the treatment of hemifacial microsomia due to Goldenhar syndrome. *J Oral Med Oral Surg.* 2022.
- [10] Hatefi S, Alizargar J, Smith F. Design and analysis of a passive continuous distraction osteogenesis device for oral and maxillofacial reconstruction. *Appl Sci.* 2024.
- [11] Li C, Liu A, Liu W, Tang X. Optimal age for mandibular distraction osteogenesis in craniofacial microsomia: a systematic review and meta-analysis. *J Stomatol Oral Maxillofac Surg.* 2025.

- [12] Adejuyigbe B, Gharpure M, Wahle CF, Kallini JR. Distraction osteogenesis: a comprehensive review. *Appl Biosci.* 2024.
- [13] Bao X, Jin M, Bai Y, Xue H, Zhao Z. Effect of trans-natural distraction osteogenesis on the nasal bone, nasal septum, and nasal airway in the treatment of midface hypoplasia in growing patients. *J Craniofac Surg.* 2023.
- [14] Al-Tamimi B, Patel B, Mills C. Distraction osteogenesis to treat sequelae of unrecognized early childhood trauma. *Plast Reconstr Surg Glob Open.* 2023.
- [15] Han W, Kim BS, Zhang Z, Chen X, Yan Y, Lin L, Zhang Y, Chai G. Changes of masseter muscle after mandible distraction osteogenesis in patients with hemifacial microsomia: a retrospective study. *Front Pediatr.* 2024.
- [16] Mao Z, Tian G, Shrivastava M, Zhou J, Ye L. Complications of mandibular distraction osteogenesis in infants with isolated Robin sequence. *Children.* 2023.
- [17] Ele He SX, Ma C, Yuan ZY, et al. Feasibility of augmented reality using dental arch-based registration applied to navigation in mandibular distraction osteogenesis: a phantom experiment. *BMC Oral Health.* 2024.
- [18] Hu W, Guo Z, Tang W, Long J. Mechanoresponsive regulation of tissue regeneration during distraction osteogenesis. *FASEB J.* 2024.
- [19] Kalay E, Ermutlu C, Yenigül AE, Yalçinkaya U, Sarisözen B. Effect of bone morphogenic protein-2 and desferoxamine on distraction osteogenesis. *Injury.* 2022.
- [20] Bernhard JC, Marolt Presen D, Li M, Monforte X, Ferguson J, Leinfellner G, Heimel P, Betti SL, Shu S, Teuschl-Woller AH, Tangl S, Redl H, Vunjak-Novakovic G. Effects of endochondral and intramembranous ossification pathways on bone tissue formation and vascularization in human tissue-engineered grafts. *Cells.* 2022.
- [21] Ma LK, Zhang ZY, Tang XJ, Xu X, Feng S, Zhao SB, Shu KY, Liu BY, Zang TY, Liu W. Respiratory outcome of mandibular distraction osteogenesis on obstructive sleep apnea in craniofacial microsomia: a retrospective study. *J Craniomaxillofac Surg.* 2023.
- [22] Pu P, Bao S, Gao J, et al. Efficacy of anterior maxillary segmental distraction osteogenesis in patients with cleft lip and palate. *BMC Oral Health.* 2024.
- [23] Wu M, Barnett SL, Massenburg BB, Ng JJ, Romeo DJ, Taylor JA, et al. Early posterior vault distraction osteogenesis changes the syndromic craniosynostosis treatment paradigm: long-term outcomes of a 23-year cohort study. *Childs Nerv Syst.* 2024.
- [24] Zhu M, Xu M, Zhang J, Zheng C. The role of Hippo pathway in ovarian development. *Frontiers in Physiology.* 2023.