

# EXPRESSION OF UNUSUAL ODONTOGENIC INFECTION: DISSEMINATION TO REGION TEMPORAL

THIAGO BRITO XAVIER<sup>1</sup>, RADAMÉS BEZERRA MELO<sup>2</sup>, YURI EDWARD SOUZA DAMASCENO<sup>3\*</sup>, THAIS DA SILVA FONSECA<sup>4</sup>, DIEGO PACHECO FERREIRA<sup>5</sup>

1. Specialist in bucomaxilofacial surgery and traumatology at the hospital universitário João de Barros Barreto of the Universidade Federal do Pará. 2. Professor at Paulo Picanço School of Dentistry (Fortaleza, CE, Brazil). 3. Resident in bucomaxilofacial surgery and traumatology in hospital universitário João de Barros Barreto of the Universidade Federal do Pará. 4. Academic of dentistry at the Universidade Federal do Pará. 5. Specialist in bucomaxilofacial surgery and traumatology at the Hospital Universitário Pedro Ernesto of the Universidade estadual do Rio de Janeiro.

\* Hospital Universitário João de Barros Barreto - Rua dos Mundurucus, Belém, Pará, Brazil. 4487. ZIP CODE: 66073-000.  
[yuri.damasceno@hotmail.com](mailto:yuri.damasceno@hotmail.com)

Recebido em 05/31/2017. Aceito para publicação em 06/25/2017

## ABSTRACT

The maxillofacial infections always pose a risk to patients, whether they are of odontogenic origin or not, are relatively common occurrence, and if not treated in properly way, it can develop rapidly and spread to adjacent anatomical structures and facial areas of the head and neck, resulting in several complications or even death; thus the treatment of this condition aims to drain the material build-up within the tissues and rehabilitate the structure and / or function of the affected area. The aim of this study is to report a case of a patient with odontogenic infection in the temporal region, which was submitted to surgical treatment with drainage of purulent collection, providing viability of this region to expel Microbiology infection. These types of infections by their high patient samples are required specific therapies for individual cases, that is, selective antibiotic associated drain pus. The amoxicillin in combination with clavulanic acid are drugs that show adequately effective against microorganisms of dental infections and usually not elicit resistance to this antibiotic to the patient.

**KEYWORDS:** Dental focal infection; Maxillofacial surgery; Drainage.

## 1. INTRODUCTION

Acute odontogenic infections are of great importance, both because of their high casuistry and the risk of complications that can compromise life in a short period of time.<sup>1</sup> Such infections are commonly self-limited, however, occasionally the purulent material may spread to the facial plans.<sup>2-3-4-5</sup>

The most frequent regions of this type of infection are the submandibular, followed by the buccal, chewing and canine, being little affected the temporal space, object of this study.<sup>4</sup> Predisposing factors, such

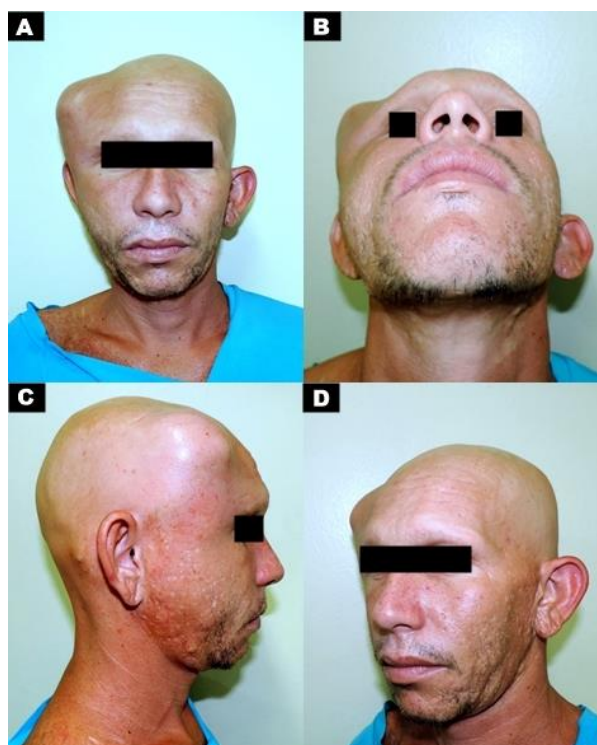as alcoholism, immunosuppression, uncontrolled diabetes mellitus and multiple underlying medical conditions are reported to increase the risk of odontogenic infection.<sup>1-2-4-5</sup>

The evolution of diagnostic methods, promotion of preventive actions against caries, the discovery of new antibiotics and the more accurate and aggressive surgical approach, together with the prevention of head and neck infections, have resulted in an increase in patient survival and a decrease in the incidence of complications. We propose, with this study, to report a clinical case of odontogenic infection in a temporal region, exposing clinical implications and therapeutic behavior performed by the Buccomaxillofacial Surgery and Traumatology team of the João de Barros Barreto University Hospital of University Federal of Pará.

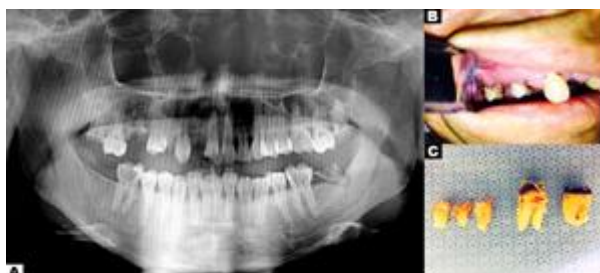## 2. CASE REPORT

A 29-year-old male patient attended the Bucomaxilofacial Surgery and Traumatology Service at the João de Barros Barreto University Hospital in Belém, Pará, Brazil, showing a hardened and well-defined volume increased in the right temporal region without skin color alteration, not heated and painless. (Figure 1 - A, B, C, and D) Patient reported evolution time of one month, he had no cervical lymphadenopathy, fever historical, or any systemic comorbidity, presenting only severe trismus. Panoramic radiography was requested to guide the diagnosis, showing no alterations or injuries of visible radiodensity in the middle third or mandible region. The intraoral examination revealed a precarious dental condition presenting dental elements compromised in the right hemimaxilla, besides showing absence of injuries, fistulas or bulging of the mucous membranes. (Figure 2 - A and B). The patient was submitted to aspiration puncture, confirming the accumulation of purulent secretion. Surgical drainage of the temporal area was made and amoxicillin and metronidazole were prescribed for the post-operative period (Figure 3 - A,

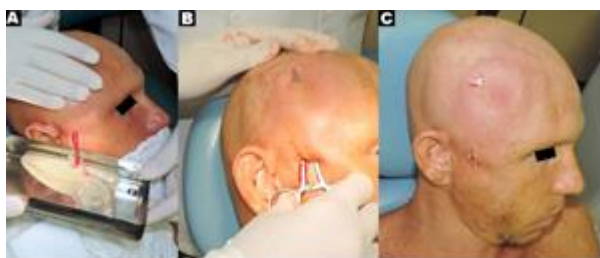
B e C).



**Figure 1:** A) Frontal aspect of infection dissemination to the temporal region. B) Bottom view and right facial asymmetry. C) Tumefaction profile aspect. D) ¾ view opposite the tumefaction.



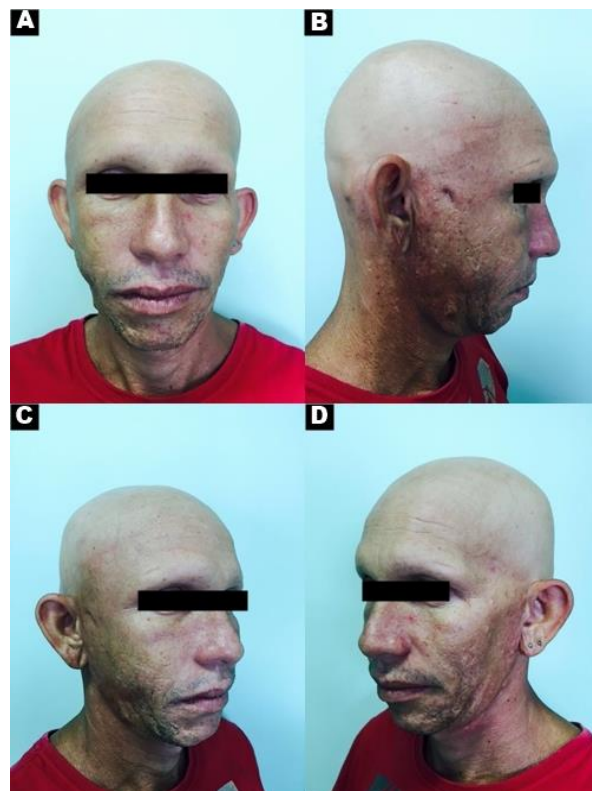**Figure 2:** A) Panoramic radiograph showing bone integrity in structures of the middle third and mandible. B) Intraoral aspect. C) Dental elements extracted by association with carious lesions.



**Figure 3:** A) Purulent collection drainage. B) Divulsion of the subcutaneous tissues. C) Temporal region in the immediate post operative period.

After one week there was a clinical improvement of the patient's condition with a significant improvement of the oral opening. Then, the dental elements with greater suspicion of association with the infectious process were removed. (Figure 2 - C) After 2 weeks of the intervention, the patient already presented total regression of swelling and edema in temporal space

with adequate facial contour, without pain complaints, trismus or sensory deficit of the facial temporal branch. (Figure 4 - A, B, C and D).



**Figure 4:** A, B, C, D) Frontal and lateral views showing total regression of infection and return of facial symmetry.

### 3. DISCUSSION

Maxillofacial infections are a public health concern, mainly when are related to those of odontogenic origin.<sup>7-8</sup> They are more common in patients who do not have access to health care and who often have their care through emergency units<sup>9</sup>. Predisposing factors, such as alcoholism, immunosuppression, uncontrolled diabetes and other conditions are reported as increased risk factors for odontogenic infection<sup>4,10</sup>.

Sato *et al.* (2007)<sup>1</sup> in a retrospective study carried out in Brazil, found that the mean age of patients affected by a maxillofacial infection was 31 years. Regarding the distribution by sex, there were no significant differences between women and men. As for racial distribution, white people were more affected, followed by blacks and whites. The main upper fascial spaces involved: buccal maxillary (19.05%) and canine (15.24%); And the buccal space (50.00%) and submandibular space (31.90%) were prominent in the mandible. As major origins were odontogenic, followed by traumatic, immunosuppressive and pathological conditions.

The progression of infection is generally fast<sup>6,11</sup>. Initial signs are characterized by hardened and diffuse tumefaction, trismus and respiratory distress<sup>2,9,12</sup>. The main symptoms are fever and dysphagia. The trismus, or difficulty of buccal opening smaller than 20mm, is a

common synthesis to several pathologies in dental practice. Among the maxillofacial infections, trismus is worth mentioning because it indicates the dissemination of the infectious process to fascial spaces<sup>2</sup>.

Contrast computed tomography is an ideal tool, not only for diagnosis, but also to determine the extent of the disease and the difference between cellulite and abscess formation. Other tools are conventional computed tomography, ultrasound, panoramic radiography, in addition to laboratory tests, microbiological cultures and antibiograms<sup>6,8,12-13-14-15-16</sup>. In this case, due to the limited and painless type of infection, the image examination used was a panoramic radiograph.

The most common odontogenic infections are caries, dentoalveolar infections, gingivitis, periodontitis, osteitis and osteomyelitis<sup>8-9,17</sup>. And they result from bacterial invasion through the periapical and periodontal tissue<sup>10,15</sup>. In situations in which the purulent collection is unable to drain through the cutaneous surface or buccal mucosa, the abscess may extend through the fascial planes of soft tissues and may cause severe complications<sup>11</sup>. When untreated, they may progress to osteoarthritis, myelitis, cellulitis, necrotizing fasciitis, abscess of myofascial spaces, lymphadenopathy, bacteremia or sepsis, all of which can be extremely lethal<sup>8-9,11,18</sup>. In the case reported, it is more likely that caries as the origin of the infection due to its stabilization after drainage and dental extractions.

Infectious dissemination to temporal space has been rarely reported<sup>6,9,12-13,19-20</sup>. Although the facial anatomy is well defined, it presents peculiar forms of infection spread, which when invaded, communicate with each other, being Capable of generating large quantities of pus, which can cause complications and / or asymmetry of the severe face, requiring a rapid and precise professional intervention<sup>13-14,20-21</sup>. The disproportionate facial asymmetry together with the severe trismus observed in this case, led the team to make its immediate external drainage of the superficial and deep compartments of the temporal region in the hospital's outpatient setting.

The types of intervention against maxillofacial infections are based on surgical drainage, antibiotic therapy<sup>5,11</sup>, extractions or endodontic teeth treatment that are the source of the infection<sup>4,11,17-18-19</sup>, in addition to hot compresses to increase vasodilation and increase circulation<sup>17</sup>. Sundaram *et al.* (2014)<sup>10</sup> reported for the first time the use of transmaxillary endoscopic drainage of an abscess in the infratemporal fossa, being another alternative of decompression.

The clinical features of an odontogenic infection are very similar to temporomandibular joint (TMJ), middle ear and salivary gland infections<sup>8,15-16</sup>, when they are disseminated in the fascial spaces. Typically, TMJ infection manifests clinically with unilateral joint involvement, spontaneous pre-auricular pain, fever, and localized erythema<sup>22</sup>. Magnetic resonance imaging helps to demonstrate degenerative and erosive changes

in the condyle<sup>23</sup>. For the clinical picture of infection of the middle ear is classically present otalgia followed by stages of the disease itself: phases of hyperemia, exudation, suppuration, mastoiditis and complication stage that occurs due to the extension of the infection besides the mucoperiosteum of the middle ear. An otoscopy is essential for the verification of normal tympanic membrane, which can be perforated during the suppuration phase<sup>24-25</sup>. Calculations, infections and edema of the salivary glands are recurrent and usually hidden by obstruction of the salivary ducts, and thus cause edema. Purulent collection may be formed by the inhibited production of saliva<sup>26</sup>. However, the salivary glands may be compressed and salivary flow normality may be observed for differential diagnosis purposes. Sialographies and biopsies are secondary tests that can be performed<sup>26-27</sup>.

## 4. CONCLUSION

Bucomaxillofacial infection dissociating to the temporal region is a rare occurrence. Thus, with the aid of imaging tests and the correct differential diagnosis, the predictable treatment can be obtained at an early stage in order to avoid further complications. Decompression of the purulent collection and antibiotic therapy are critical to a successful treatment.

## 5. REFERENCES

- [1] Sato FRL, Hajala FAC, Filho FWVF, *et al.* Eight-Year Retrospective Study of Odontogenic Origin Infections in a Postgraduation Program on Oral and Maxillofacial Surgery. *J Oral Maxillofac Surg* 2009; 67:1092-1097.
- [2] Peterson LJ, Ellis E, Hupp JR, *et al.* *Cirurgia Oral e Maxilofacial Contemporânea*. 4ª ed. Rio de Janeiro: Elsevier; 2005.
- [3] Azenha MR, Lacerda SA, Bim AL, *et al.* Celulite facial de origem odontogênica. Apresentação de 5 casos. *Rev. Cir. Traumatol. Buco-Maxilo-Facial, Camaragibe* 2012;12(3):41-48.
- [4] J. Wang, A. Ahani, M. A. Pogrel. A five-year retrospective study of odontogenic maxillofacial infections in a large urban public hospital. *Int. J. Oral Maxillofac. Surg.* 2005; 34:646-649.
- [5] Martínez RG, Ballester IC, Vilas JMH, *et al.* Antibiotic prescription in the treatment of odontogenic infection by health professionals: A factor to consensus. *Med Oral Patol Oral Cir Bucal*. 2012; 17(3):452-6.
- [6] Jardim ECG, Santiago Júnior JF, Guastaldi FPS, *et al.* Infecções odontogênicas: relato de caso e implicações terapêuticas. *Revista Odontológica de Araçatuba*. 2011; 32(1): 40-43.
- [7] Park SY, Suh DW, Park, CM, *et al.* Brain abscess due to odontogenic infection: a case report. *J Korean Assoc Oral Maxillofac Surg* 2014; 40:147-151.
- [8] Gallagher J, Marley J. Infratemporal and submasseteric infection following extraction of a non-infected maxillary third molar. *Br Dent J*. 2003; 194(6):307-9.
- [9] Mesgarzadeh AH, Ghavimi MA, Gok G, *et al.* Infratemporal space infection following maxillary third molar extraction in an uncontrolled diabetic patient. *J Dent Res Dent Clin Dent Prospect*. 2012; 6(3):113-115.



- [10] Sundaram SS, Rajan P, Balasubramanian A. Endoscopic transmaxillary drainage of an infratemporal fossa abcess. *BMJ Case Rep.* 2014; 30:2014.
- [11] Al-Qamachi LH, Aga H, McMahon J, *et al.* Microbiology of odontogenic nfctions in deep neck spaces: A retrospective study. *Br J Oral Maxillofac Surg.* 2010; 48(1):37-9.
- [12] Sánchez R, Mirada E, Arias J, *et al.* Severe odontogenic infections: Epidemiological, microbiological and therapeutic factors. *Med Oral Patol Oral Cir Bucal.* 2011; 16 (5): 670-6.
- [13] Kasahara K, Ogawa C, Matzusaka K, *et al.* A case of infratemporal fossa abcess with signs of chronic maxillary osteomyelitis. *Bull Tokyo Dent Coll.* 2015; 56(2): 121-129.
- [14] Statkiewicz C, Faverani LP, Gomes-Ferreira PHS, *et al.* Misdiagnosis of Extensive Maxillofacial Infection and Its Relationship with Periodontal Problems and Hyperglycemia. *Case Reports in Dentistry.* 2016; 2016:5960546.
- [15] Kataria G, Saxena A, Bhagat S, *et al.* Deep Neck Space Infections: A Study of 76 Cases. *Iran J Otorhinolaryngol.* 2015; 27(81):293-9.
- [16] Ko IC, Yoon KH, Park KS, *et al.* An unusual abscess formation in the masticator space after acupressure massage: a case report. *J Korean Assoc Oral Maxillofac Surg.* 2015; 41:52-56.
- [17] Bahl R, Sandhu S, Singh K, *et al.* Odontogenic infections: Microbiology and management. *Contemp Clin Dent.* 2014; 5(3): 307–311.
- [18] Han X, An J, Zhang Y, *et al.* Risk Factors for Life-Threatening Complications of Maxillofacial Space Infection. *J Craniofac Surg.* 2016; 27(2):385-90.
- [19] Flynn TR, Shanti RM, Levi MH, *et al.* Severe Odontogenic Infections, Part 1: Prospective Report. *J Oral Maxillofac Surg.* 2006; 64:1093-1103.
- [20] Flynn TR, Shanti RM, Hayes C. Severe Odontogenic Infections, Part 2: Prospective Outcomes Study. *J Oral Maxillofac Surg.* 2006; 64:1104-1113.
- [21] Bali RK, Sharma P, Gaba S, *et al.* A review of complications of odontogenic infections. *Natl J Maxillofac Surg.* 2015; 6(2):136-43.
- [22] Pintor FR, Carrasco R, Verdugo-Avello F, *et al.* Artritis infecciosa de la articulación temporomandibular consecutivo a otitis necrotizante: reporte de un caso. *Rev Med Chile* 2015; 143: 805-808.
- [23] Ayachi S, Mziou Z, Moatemri R, *et al.* Bilateral septic arthritis of the temporo mandibular joint: case report. *Pan Afr Med J.* 2016; 25: 100.
- [24] Kocyigit M, Ortekin SG, Cakabay T, *et al.* Frequency of Serous Otitis Media in Children without Otolaryngological Symptoms. *Int Arch Otorhinolaryngol.* 2017; 21(2):161-164.
- [25] Schilder AGM, Bhutta MF, Casselbrant ML, *et al.* Panel 7: Otitis Media: Treatment and Complications. *Otolaryngol Head Neck Surg.* 2017; 156(4): S88-S105.
- [26] Gallo A, capaccio P, benazzo M, *et al.* Outcomes of interventional sialendoscopy for obstructive salivary gland disorders: an Italian ulticentre study. *Acta Otorhinolaryngol Ital.* 2016 Dec;36(6):479-485.
- [27] Kimura M, Enomoto A, Shibata A, *et al.* A Case of Sialolithiasis in a Minor Salivary Gland of the Buccal Mucosa. *J Clin Diagn Res.* 2016; 10(11):ZD06-ZD07.