Journal of Surgical and Clinical Dentistry

Online ISSN 2358-0356

JSCD

12(1)

January / March

2017

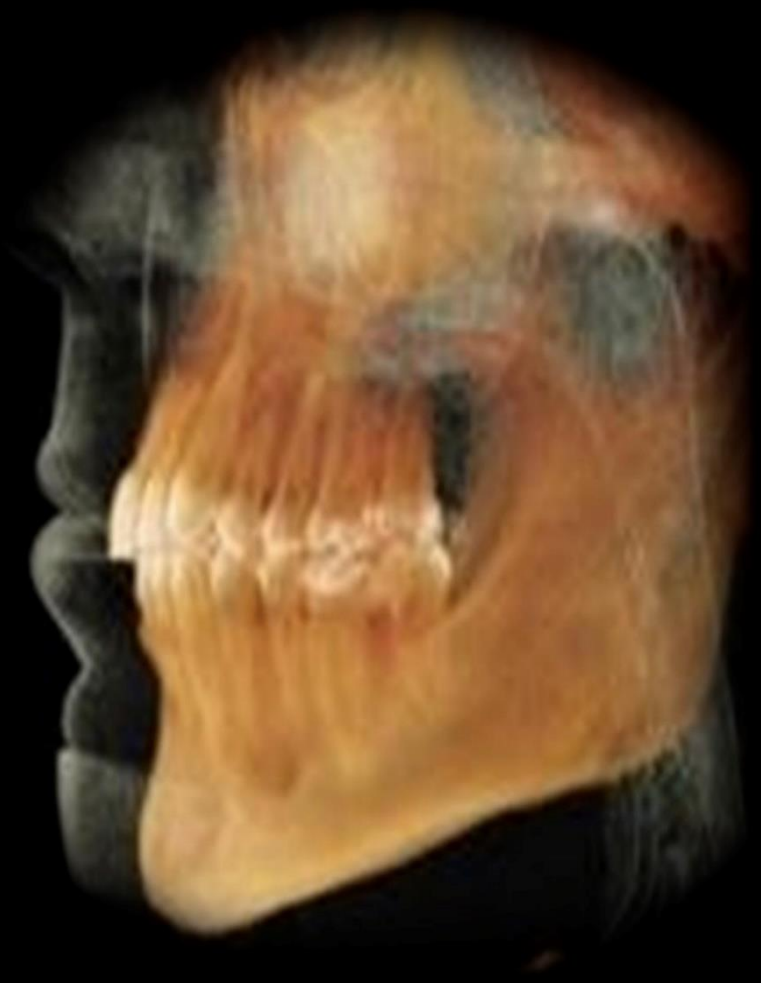

MASTER EDITORA
Publicações Científicas

Online ISSN 2358-0356

JSCD Technical Specifications

Title: Journal of Surgical and Clinical Dentistry
Short title: J. Surg. Clin. Dent.
Abbreviation: JSCD
Publisher: Master Editora
Periodicity: Quarterly
Indexed: Latindex, Google Scholar, EBSCO host
Start: April, 2014

*The **Journal of Surgical and Clinical Dentistry - JSCD** is an editorial product of the **Master Publisher** aimed at disseminating scientific articles only in electronic media, indexed in Latindex, Google Scholar and EBSCO host database.*

*All articles published were formally authorized by the authors and are your sole responsibility. The opinions expressed by the authors of the published articles do not necessarily correspond to the opinions of **Master Publisher**, the **JSCD** and/or its editorial board.*

Master Editora
The Brazilians open access Journals

Online ISSN 2358-0356
JSCD

Editorial

Dear Researcher,

We have the great pleasure to entry the twelfth edition, volume one, of the ***Journal of Surgical and Clinical Dentistry - JSCD****.*

The ***Master Publisher*** *and the* ***JSCD*** *are very grateful to the authors of the articles that brighten this edition of the invaluable collaboration, by immediately accepted our invitation and for the trust placed in this project.*

The ***JSCD*** *is one of the early open access Journal in Brazil, representing the materialization of the lofty ideals of* ***Master Publisher*** *about the broad and unrestricted dissemination of scientific knowledge produced by the Health Sciences.*

Authors of scientific articles that are interested in the scope of ***JSCD****, send your manuscripts for consideration of our editorial board!*

Our thirteenth edition will be available in April, 2017!

Happy reading!

Mário dos Anjos Neto Filho
Editor-in-Chief JSCD

Online ISSN 2358-0356

JSCD

Summary

CASE REPORT

ASSISTED SEDATION AS AN ALTERNATIVE FOR NON-COLLABORATIVE CHILDREN: CASE REPORT

KARLINE KATIUSCIA **TAKEMOTO**[1*], TEREZA CRISTINA ROSCHEL **GIFFONI**[2], LUCIMARA CHELES DA SILVA **FRANZIN**[3], ERMELINDA **MATSUURA**[4], PATRICIA SARAM **PROGIANTE**[5], SUZANA **GOYA**[6]

1. Undergraduate Student in Dentistry, UNINGÁ; **2**. Professor of Dentistry at the UNINGÁ; **3.** Dentist, PhD by PUC-PR, Professor of Dentistry at the UNINGÁ; **4**. Master in Integrated Dentistry by UEM, Professor of Dentistry at the UNINGÁ; **5**. Dentistry, Post-Doctor in Health Sciences by FOB-USP). Professor of Dentistry at the UNINGÁ; **6.** Dentistry, PhD in Applied and Pure Sciences - Collective Health by FOB-USP, Professor of Dentistry at the UNINGÁ.

* Mamborê Street, 1634, Downtown, Campo Mourão, Paraná, Brazil . ZIP CODE: 87302140. karlinetakemoto20@hotmail.com

Received: 07/29/2016. **Accepted:** 10/10/2016

ABSTRACT

Anxiety and fear are factors that can harm dental practice in adults and children. There are children who are anxious and afraid and due to the fact that they cannot overcome this fear they are classified as non-collaborative. If there is no cooperation even after using all handling techniques and physical constraint for the treatment of these children, pharmacological techniques such as assisted sedation are used. With a good indication, careful planning and skill of the dentist professional, it is a technique with a good clinical outcome and that prevents psychological trauma. It is presented in this report of clinical case, the use of deep sedation also named assisted sedation, as a second treatment option, after the rejection of conventional treatment techniques for the 4 year-old child in 10 clinical sessions management with the pedodontist.

KEYWORDS: Sedation; analgesia; anxiety; dentistry.

1. INTRODUCTION

Dental practice was and still is classified by a portion of the population as an unpleasant experience. According to Malamed (1996)[1] the dental consultation was considered the second greatest fear of the population described as an unpleasant experience in which there is pain, discomfort, noises and strong odors.

Therefore some patients will present the sensation of discomfort or fear during dental care[2]. In dentistry this fear can be transient or not being classified in objective fear when the threat is real or subjective when it is induced or imaginary[3].

Concomitantly to fear there is anxiety that is considered a psychic state of apprehension or fear caused by anticipation of an unpleasant or dangerous situation and is present in non-collaborative children to dental treatment, significantly altering the physical and psychological state of the patient[4].

In pediatric dentistry it is verified that the behavior of the child during dental care is essential for the success of non-pharmacological clinical treatment[5]. The caregiver should be attentive to the child's reactions before, during and after clinical care to see if they are positive or negative in order to avoid causing trauma[6].

There are several techniques used to control infant behavior during dental treatment that may be known as management techniques. Associated with the linguistic domain, child management techniques are procedures that aim to prevent and alleviate fear and anxiety, establish good communication and educate the patient by encouraging them to cooperate during dental treatment[7]. Pediatric dentistry may be pharmacological and non-pharmacological techniques[8].

The non-pharmacological techniques have the purpose of managing the child's behavior to provide safety and tranquility to the child and their parents[9] and are: Nonverbal communication, physical touch, talk-show-doing, desensitization, modeling, distraction, positive reinforcement, negative reinforcement, voice control and physical immobilization[10].

In cases of intense fear and anxiety in which the child does not cooperate and management techniques are ineffective, there is a need for the use of pharmacological techniques in order to obtain the maximum therapeutic result but with the least adverse reactions to the child. Conscious inhalation sedation and general anesthesia are the most commonly used pharmacological techniques in pediatric dentistry[11].

2. LITERATURE REVIEW

According to Macdonald (2011)[12] there is a classification by the American Academy of Pediatric Dentistry (AAPD) for sedation levels that are: minimal sedation, moderate sedation, deep sedation.

Minimal Sedation is defined as an altered or depressed state of the patient's level of consciousness caused by medications, which does not affect their ability to maintain airways and cardiovascular function independently and continuously, as well as the ability to respond appropriately, To physical stimuli and verbal command even if

cognitive functions and coordination are compromised.

In moderate sedation there is depression of drug-induced consciousness, during which the patient responds intentionally to a verbal command and / or a slight tactile stimulus. No intervention is required to keep the airway permeable and spontaneous ventilation is adequate and cardiovascular function is normal.

And deep sedation is one in which the patient is with most of his or her reflexes depressed and may be without spontaneous breathing[12].

The American Dental Association - ADA (1997) defined deep sedation and general anesthesia as being a controlled state of unconsciousness, accompanied by partial or complete loss of protective reflexes, including the ability to breathe independently and voluntarily respond to physical stimulation or verbal command, which is produced by pharmacological method, non-pharmacological or their combinations[13].

The dentist surgeon must be able to perform conscious sedation and master the technique of choice. For sedation is used benzodiazepines that have hypnotic and sedative properties or inhalation by nitrous oxide considered a sedative agent, in cases of requiring conscious sedation of minimal or moderate level. The choice of medication, technique or the association of both without a dental office should be used responsibly and with the professional's broad knowledge of Law No. 5081 of August 24, 1966, which in article 6, item VI, Explains that the dental surgeon can apply analgesia, provided that it is proven and when its use is an effective means of treatment and resolution 51/04 of the CFO (Federal Council of Dentistry) that establishes the need for a 96-hour course to Enable the dental surgeon to apply relative analgesia or conscious sedation that will be formally trained to perform such procedure from the pharmacology, routes of administration, and recovery of the patient[14].

In cases in which the professional opts for a deep sedation he should have a qualified team and only the anesthesiologist can proceed in this technique of sedation in an ambulatory or hospital environment, with monitoring equipment, because in this level of sedation the patient should be Assisted during and after the procedure and even in the case of benzodiazepine sedation, nitrous oxide inhalation or deep sedation, the use of analgesia by local anesthetics is not ruled out, responses to the use of these drugs are individual and levels are continuous, occurring with Frequency, the transition between them[15]. The physician prescribing or administering the medication should have the ability to recover the patient from this level or maintain it and recover it from a state of greater depression of cardiovascular and respiratory functions[16].

As noted in the world literature, sedation has been used quite successfully after proper patient selection, careful and documented planning and use of the indicated technique with the aim of minimizing the psychological trauma of a conventional treatment and maximizing the potential of Amnesia caused by sedation[17].

3. CASE REPORT

A 4-year-old female child entered the dental clinic accompanied by the mother with major complaint of tooth pain due to multiple dental caries. The legal guardian, in the case of the mother, reported in the anamnesis that general health is good, with no history of childhood diseases or other types of systemic problems, did not present any type of allergic reaction to medications and local anesthesia, feeding was with Homemade food and daily oral hygiene.

After signing the clinical file, the Term of Free and Informed Commitment, authorization for use of the image was initiated clinical care.

In the extra-oral evaluation, it presented a normality pattern. In the intra-oral evaluation, the lips, cheek, tongue, hard and soft palate, lingual floor and gingiva were examined and found to be unchanged.

In the evaluation of caries risk, a diagnosis of carious lesion was made on the following elements: 51, 52, 54, 55, 61, 62, 64, 65, 74, 75, 84 and 85. Elements 53, 63, 73, 72, 71, 81, 82 and 83 are healthy (Figure 1, 2 and 3).

Figure 1. Intraoral frontal view with multiple carious lesions in elements 52, 54, 55, 61, 62, 64, 65 and total destruction of the crown of 51.

Figure 2. Intraoral view with carious lesion on elements 74 and 75 in the occlusal.

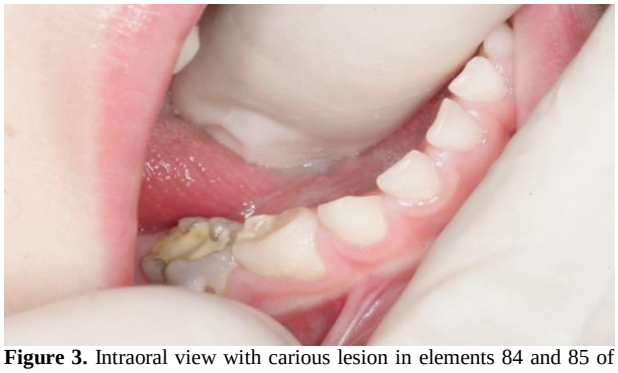

Figure 3. Intraoral view with carious lesion in elements 84 and 85 of this occlusal.

The proposed treatment plan was preventive treatment (oral hygiene instruction, prophylaxis and topical application of fluoride) and restorative treatment (adjustment of the buccal medium for later restorative treatment). Therefore, the health education for the child and the mother was initiated through oral hygiene instruction and diet recommendations with the accomplishment of management technique with child in the dental chair.

However, after 10 sessions of clinical management and the refusal of the child's collaboration in dental care, due to the child's immaturity and the clinical conditions of the mouth, all procedures were performed in an outpatient clinic with assisted sedation.

Induction for sedation and the clinical procedure started at 08:00 am and ended at 12:15 a.m., with a duration of 4 hours of clinical care.

The medications used by the anesthetist to induce analgesia were Dormonid syrup 0.5 mg per kg (1.25 mg) as pre-anesthetic medication; Fentanyl 1 to 2 mcg per kg (50 mg); Propofol 1 to 1.5 mg/ kg (70mg); Propofol in pump 100 mcg/ kg in minute (15 mL/ 1 h).

Midazolam is the benzodiazepine of choice for short-acting sedation, has a short half-life, being 2 to 4 times more potent than Diazepam. Because it is water soluble, it is painless both in intravenous and intramuscular administration.

Fentanyl is a semi-synthetic opioid with rapid onset of action is 100 times more potent than morphine, it is the opioid of choice for analgesia in short procedures. It has few cardiovascular effects, releases less histamine, but can cause stiffness of the rib cage, especially after rapid intravenous infusion that can be reversed with the use of antagonistic drugs or with muscle relaxants.

Propofol is an ultra fast acting anesthetic agent, inducing immediate sedation. Its great advantage relates to the rapid sedative effect[19].

The medications given were the antibiotic Cefazoline 25 mg per kg (625 mg); corticosteroids Dexamethasone 0.1 mg per kg (2.5 mg), Ondansetron 0.1 mg per kg (2.5 mg) and analgesic Dipyrone sodium 20 mg per kg EV (500 mg) (Figure 4a And Figure 4b). Cefazolin is antibacterial cephalosporin of 1st generation; Beta-lactam; Cefazolin sodium.

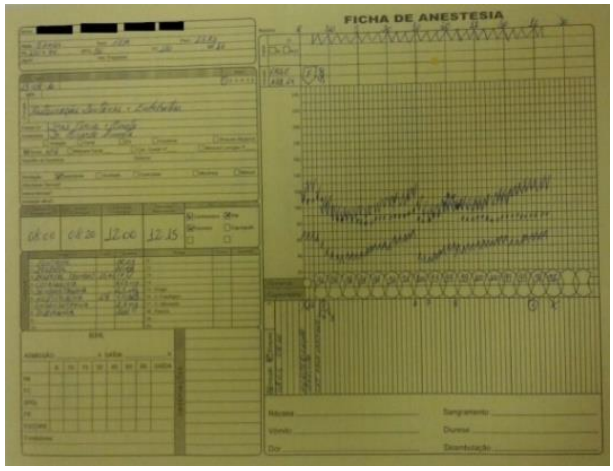

Figure 4 a. Medications used; **Figure 4b**- Anesthesia card (The operating room should be equipped with ventilatory support, multi-parameter monitor).

Figure 5. Ventilatory support.

Dexamethasone has potent anti-inflammatory action[20]. Ondansetron is indicated for the control of nausea and vomiting induced by chemotherapy, radiotherapy and also indicated for the prevention and treatment of postoperative nausea and vomiting.

Dipyrone has analgesic, antispasmodic and antipyretic action in Brazil, it is widely used in the treatment of mild pain, and synergism with opioids in the treatment of moderate and intense pain, and it can be used orally, venous and rectally[21].

Figure 6. Multi-parameter monitor.

Figure 7. Oxygen torpedo and defibrillator for patient monitoring, induction and recovery.

After sedation, clinical care was started by performing local infiltrative anesthesia with the use of 4 tubes of the local anesthetic Mepivacaine at 2%. After the anesthesia, the endodontics of element 51 begins and crown is made in composite resin with glass fiber pin cemented with zinc phosphate, cervical vestibule restoration in composite resin of element 52.

In element 61 there was the vestibule restoration and class IV in composite resin color A1. The element 62 received a mesial restoration in composite resin (Figure 8). As a precaution, an upper impression was made for the preparation of an apparatus if the element 51 could fracture.

Figure 8. Frontal view after the end of treatment in the maxilla region.

In element 54, endodontics with CTZ (chloramphenicol, tetracycline, zinc oxide and eugenol) was performed, and the insertion of CIV (Glass Ionomer Cement) and restoration in composite resin and composite resin restoration element occlusal and sealant application (Figure 9).

Figure 9. View of the upper right region after completion of endodontics, restorations and sealant application.

In element 64, endodontics was performed with CTZ medication and the insertion of CIV (Glass Ionomer Cement) and restoration in composite resin and then restoration of element 65 in composite resin in the occlusal and palatine and the application of sealant (Figure 10).

After the upper maxillary region was finished, treatment of the lower region with the restoration in composite resin, application of sealant in element 74 in

element 75, endodontics with CTZ medication, a guiding CIV base and restoration with composite resin (Figure 11).

Figure 10. View of the upper left region after completion of endodontics, restorations and sealant application.

In element 84 there was a need for indirect pulp capping with calcium hydroxide cement (Dycal®), use of VIC as a backing material and restoration in composite resin in occlusal and distal and application of sealant.

In the 85-pulp cap element with Dycal® IVC lining and restoration in composite resin in the occlusal and vestibular (Figure 12).

Figure 11. View of the lower left after completion of restorations.

Figure 12. Side view of the lower right region.

Faced with a dentistry dental treatment made difficult by the patient's non-cooperation and after the attempt of all the management techniques, we can have pharmacological techniques for the control of anxiety and the cooperation of the child, to obtain a good clinical result in the short term. Therefore, it is up to the dental surgeon to analyze which behavior to take through a non-collaborative child, presenting and deciding with the parents what the sedative behavior to be chosen.

4. CONCLUSION

Sedation techniques, when well indicated and employed, have a high acceptance rate due to the good clinical outcome and the maintenance of the physical and psychological integrity of the child.

REFERENCES

[01] Mallamed ST. Painandanxietycontrol in Dentistry. Oral Health 1996 Feb; 86 (2): 11-16.

[02] Góes MPS, Domingues MC, Couto GBL, Barreira AK. Ansiedade, medo e sinais vitais dos pacientes infantis. Odontol. clín.-cient (2010): 39-44.

[03] Cogo K, Bergamaschi CC, Yatsuda R, Volpato MC, Andrade ED. Sedação consciente com benzodiazepínicos em odontologia. Odontologia da Universidade Cidade de São Paulo 2006; 18(2): 181-8.

[04] Seger L. Psicologia e odontologia uma abordagem integradora. 4ª ed. São Paulo: Santos; 1998.

[05] Teixeira TF, Quesada GAT. Terapia ansiolítica para pacientes odontológicos. Saúde (Santa Maria) 2004; 30(2): 100-103.

[06] Moraes ABA, Sanchez KAS, Possobon RF, Costa Junior AL. Psicologia e odontopediatria: A contribuição da análise funcional do comportamento. Psicologia 2004; 17(1): 75-82.

[07] Josgrilberg EB, Cordeiro RCL. Aspectos psicológicos do paciente infantil no atendimento de urgência. Odontologia Clínica Cíentifica. Recife 2005; 4(1); 13-18.

[08] Cogo K, Bergamaschi CC, Yatsuda R, Volpato MC, Andrade ED. Sedação consciente com benzodiazepínicos em odontologia. Odontologia da Universidade Cidade de São Paulo 2006; 18(2): 181-8.

[09] Ferreira JMS, Aragão AKR, Colares V. Técnicas de controle do comportamento do paciente infantil: revisão de literatura. Pesqui Bras Odontopediatria Clín Integr 2009; 9(1): 247-251.

[10] Guedes-Pinto AC, Bönecker M, Rodrigues CRMD. Odontopediatria - Fundamentos em Odontologia. São Paulo: Santos-GEN 2009; 9(1): 301-328.

[11] Oliveira ACB, Pordeus IA, Paiva SM. O uso do óxido nitroso como uma opção no controle de comportamento em odontopediatria. J Bras Odontopediatr Odontol Bebê 2003; 6(32): 344-50.

[12] McDonald RE, Avery DR, Dean JA, Odontopediatria para crianças e adolescentes. Rio de Janeiro. Elsevier 2011.

[13] Neta C *et.al*. O uso de óxido nitroso/oxigênio na clínica odontológica. Pernambuco 2014 [Trabalho de Conclusão de Curso], [acesso em 11 de Agosto de 2016] Disponível

em:>
http://dspace.bc.uepb.edu.br/jspui/bitstream/123456789/4209/1/PDF%20-%20Maria%20Catarina%20da%20Costa%20Neta.pdf <.

[14] nome dos autores. Saúde Bucal: Odontopediatria para crianças e adolescentes. Conselho Federal de Odontologia 2014. [acesso 11 de março de 2016] Disponível em: http://cfo.org.br/

[15] Brasil. Resolução do Conselho Federal de Odontologia – CFO 51/04 [acesso 23 de maio de 2016] Disponível em: http://www.portalmedico.org.br/resolucoes/CFM/2003/1670_2003.htm

[16] McDonald RE, Avery DR, Dean JA, Odontopediatria para crianças e adolescentes. Rio de Janeiro. Elsevier 2011.

[17] Benseñor FEM & Cicarelli DD. Sedação e Analgesia em terapia intensiva. Rev Bras Anestesiol 2003; 53(5): 680 – 693.

[19] Brunton LL, Bruce AC, Björn CK. As Bases Farmacológicas da Terapêutica de Goodman & Gilman-12. AMGH 2012; 3(1): 63-72.

[20] Mello MAO, Silva YP. Sedação e analgesia em pronto atendimento pediátrico. Rev Med Minas Gerais 2010; 20(4): 37- 46.

[21] Silva YP, Silva JF, Costa LP, Medeiros MF, Mota JAC. Sedação e Analgesia em pronto atendimento pediátrico: Artigo de Revisão. Revista de Medicina de Minas Gerais 2005; 15(2): 105-110.

ANGINA OF LUDWIG ARISING OUT OF ENDODONTIC INFECTION: A CASE REPORT

KARINA **ARAÚJO**[1], ISABELA **GREGANINI**[1], ALBERTO FABIO **LIMA**[2], ANGELA MELO **PRÊMOLI**[2], VANESSA RODRIGUES DO **NASCIMENTO**[3], LUIZ FERNANDO **TOMAZINHO**[4*]

1. Student's undergraduate degree in Dentistry at the University Paranaense – UNIPAR; **2.** Dental Surgeon, Endodontic Specialist; **3.** Specialist in Endodontics Master in Radiology, Dentistry Course Professor at the University Paranaense – UNIPAR; **4.** Specialist in Endodontics, USP-SP PhD, Professor of Dentistry Course at the University Paranaesnse - UNIPAR.

* Inaja Street, no 3560, Ap 42 Centro, Umuarama, Paraná, Brazil. ZIP CODE: 87501-160. tomazinho@unipar.br

Received: 07/29/2016. **Accepted:** 10/10/2016

ABSTRACT

The Ludwig's angina is a cellulite described by Wilhelm Frederick von Ludwig 1836 which is often originates from an odontogenic infection (representing about 70% of cases) classically located in the second and third molars, which involves the space submandibular, sublingual and submental. The apexes of these teeth are precisely located below the insertion of the mylohyoid muscle, thus being in close anatomical relation to the submandibular space. In any tooth infection, the subsequent drilling of the cortical jaw in contact with the language will lead to progression of the process in the submandibular, sublingual and submental spaces. Ludwig angina that are of dental origin, tend to be more serious and severe than those of other causes, may have higher systemic complications. The association of dental caries can make more aggressive, with a rapid spread. This situation requires surgery and early tracheostomy added to clinical treatment protocols. The protocol of care must be rigorous, always aiming at the drainage of the purulent collection, the removal of the causal agent, the maintenance of the antimicrobial agents and the stabilization of the patient. The professional team's expertise in diagnosing the condition, combined with skill and rapid care, were critical to successful treatment.

KEYWORDS: Ludwig's angina, endodontic infection, systemic complications

1. INTRODUCTION

Most odontogenic infections originate from pulpal necrosis with bacterial invasion in the periapical and periodontal tissue, the accumulation of inflammatory cells at the apex of a necrotic tooth can lead to abscess formation, when the infection prevails over the host's resistance. These abscesses may be symptomatic or asymptomatic since the acute and chronic classification becomes inadequate because both types represent acute inflammatory reactions. The periapical abscess becomes symptomatic when the purulent material accumulates in the alveolus[1].

When this purulent secretion spreads through the bone marrow spaces or cortical surfaces of the bone results in a process called osteomyelitis, and when it diffuses through the soft tissues, cellulite forms. Once localized in the soft tissues this abscess can be channeled through the suprajacent soft tissue where the cortical can be perforated in a place that allows its penetration into the oral cavity or through the suprajacent skin and drain by a cutaneous fistula. If the abscess is not able to drain through the oral cavity or the skin surface, it extends through the soft tissue facial planes in a diffuse form forming what we call cellulite and the most common types are Ludwig's Angina and thrombosis of the Cavernous sinus. Cavernous sinus thrombosis presents as a periorbital edema-like enlargement with involvement of the eyelids and conjunctiva, with protuberance and fixation of the eyeball, progression may involve the central nervous system.

Ludwig's angina

Ludwig's angina is a cellulitis described by Wilhelm Frederick von Ludwig in 1836, which is frequently originated from an odontogenic infection (corresponding to almost 70% of the cases) classically located in the second and third lower molars, which involves submandibular, sublingual and submental space. The apexes of these teeth are located just below the milo-hyoid muscle insertion, being consequently in an intimate anatomical relation with the submandibular space. In the eventual dental infection, the subsequent perforation of the cortical of the mandible in contact with the tongue will lead to the progression of the process in the submandibular, sublingual and submental spaces[2].

Although in the vast majority of cases the focus is of odontogenic origin, infection of palatine tonsils, sialoadenites, epiglottitis, and infected thyroglossal cyst are infectious foci reported as the etiology of Ludwig's angina, as well as: infection of a jaw fracture, perforating wound of mouth floor[3].

The presence of dental caries, oral trauma, immunodepression and the continuous use of psychoactive sub-

stances such as alcohol and drug abuse are predisposing factors for this infection. Typical symptomatology includes pain, cervical enlargement, dysphagia, odynophagia, trismus, buccal edema, lingual protrusion, fever, lymphadenopathy and chills[4] .

For the diagnosis of Ludwig's Angina, the following characteristics should be observed: it begins at the floor of the mouth, usually with infection of the 2nd or 3rd lower molar; dissemination occurs to the submandibular space, more contiguity, by the planes of the fascia, Than by the lymphatic vessels; The infection presents as hardening of the submandibular region, without formation of much purulent secretion; The process saves the salivary glands and lymph nodes; Is usually bilateral[5].

Ludwig's Angina treatment is based mainly on the triad, maintenance of the patent superior airways, appropriate intravenous antibiotic therapy and surgical drainage, considering parenteral hydration and removal of the infectious focus. The maintenance of patent airways is an important step in the success of treatment, since infection can lead to respiratory obstruction quickly. In such cases, a tracheostomy or cricothyroidostomy should be indicated in the maintenance of airways[6], although it should be remembered that this procedure may result in a greater spread of infection, making the procedure dangerous, under these conditions[7].

2. CASE REPORT

A Patient ASV, male, 32 years old, drug user, alcohol, cigarette presented to the Health Station of Nova Ubiratã-MT with high fever, general malaise generalized pain and inflammatory process in the anterior cervical region, edema, flushing, Pain, trismus. The radiographic examination shows destruction of the third right lower third molar caused by carious lesion as shown in Figure 1.

Figure 1. Initial panoramic radiography.

The clinical examination performed by the dentist at the health clinic showed an increase in the volume of the sub-colon and submandibular bilateral regions of hardened consistency (Figures 2A and 2B). According to Shafer (1985)[1], the patient can be diagnosed with Angina of Ludwig, where he presents a classic picture of signs and symptoms as a firm, diffuse and painful swelling in the floor of the mouth, with no evidence of fluctuation and no absence of depression of the tissues when pressed.

Figure 2. Preoperative images.

Physically, the patient presented febrile, septic, reporting gastric intoxication due to abuse of analgesics, hyperemia in the cervical region associated with hyperthermia and limitation of mouth opening. The patient's oral hygiene picture was deficient, justifying the gingivitis presented.

The patient was referred to Hospital Regional de Sorriso - MT, where he was hospitalized and treated with antibiotics (clindamycin and ceftriazone). On the following day, under general anesthesia and orotracheal

intubation, surgical drainage and extraction of element 48 were performed, which would be the causal factor for all infections. After the second day of hospitalization, there was a notable improvement in his clinical condition, which continued to evolve to cure throughout hospital care. On the tenth day of hospitalization, the patient was discharged and was referred to the health clinic of Nova Ubiratã to continue performing the periodic exchanges of topical dressings according to Figures 3A and 3B.

Figure 3. Local asepsis and dressings.

The patient was under clinical control until its complete recovery And healing of the surgery, which took 21 days. (Figures 4A and 4B).

3. DISCUSSION

Preventing the respiratory airways from being clogged is a major goal in any treatment. Dyspnea, tachypnea, tachycardia, wheezing, restlessness, and the patient's need to maintain an upright posture suggest obstruction of these respiratory airways. Parallel to these signs, symptoms such as fever, leukocytosis and a high erythrocyte rate can also be observed. These symptoms are classically observed in purulent collections[8].

The antibiotic therapy regimen may be established based on high doses of penicillin G and may be combined with other agents, such as metronidazole, clindamycin or cefoxitin, until the establishment of the definitive scheme based on culture and antibiogram[9]. According to this team of researchers, preoperative and postoperative antibiotic therapy is part of the treatment for Ludwig's Angina, and a previous attack dose should be performed.

Figure 4. AA - Exchange of local dressing; B- Complete wound healing.

In a survey conducted between 2009 and 2013, Marcato (1997)[10] analyzed medical records of UEL's Regional University Hospital (HURNP), which concluded that of the 108 patients with odontomic infection, 9 evolved to Ludwig's Angina, and that all patients needed treatment in a hospital surgical center (orotracheal intubation, tracheostomy and cricothyroididotomy) for

maintenance of the airways and, thus, mortality prevention, and all patients treated at HURNP received as antibiotic-initial therapy the hospital protocol of Clindamycin 600 mg IV, every 6 hours in combination with Ceftriaxone 1g IV every 12 hours.

Our clinical management of the case was based on previous procedures reported by Kurien *et al.* (1997)[11], where Ludwig's Angina's that are of dental origin are usually more severe and severe than those of other causes and may present greater systemic complications. The association of dental caries can make it more aggressive, with rapid dissemination. This situation requires surgical intervention and early tracheostomy in addition to clinical treatment protocols.

Ludwig's Angina usually has a polymicrobial character, composed of aerobic, facultative and anaerobic, which are part of the resident microbiota and colonize the oropharynx, being species such as Streptococcus, Staphilococcus and Bacteroides commonly found[12].

The clinical case is of dental origin, related to the third right lower third molar. The origin and course of the infection were periapical or periodontal, because of the position of the apex of the root in relation to the milo-hyoid crest in agreement with Shafer (1985)[1]. Also the thinner thickness of the alveolar process on the lingual aspect of the mandible caused the infection to erupt into the submandibular space. Due to the state of oral hygiene presented by the patient, it suggests that the septicity of the buccal medium may have contributed to the onset of infection associated with pulp necrosis[13].

4. CONCLUSION

Patients with Ludwig's angina, which is a severe, rapidly progressive infection, should be treated with immediacy, as they may lead to serious complications, or even death. The protocol of care should be rigorous, always aiming at drainage of the purulent collection, removal of the causal agent, maintenance of antimicrobial agents and stabilization of the patient. The professional team's expertise in diagnosing the condition, combined with skill and rapid care, were critical to successful treatment.

REFERENCES

[1] Shafer WG. Tratado de patologia bucal. Rio de Janeiro: Interamericana. 1985.

[2] Little C. Ludwig`s angina. Dimens Crit Care Nurs. 2004; 23 (4):153-4

[3] Zanini FD, *et al.* Angina de Ludwig: relato de caso e revisão de manejo terapêutico. ACM Arq Catarin Med. 2003; 32(4):21-3

[4] Ferrera PC, Busino LJ, Snyder H. S.Uncommon complications of odontogenic infections. Am J Emerg Med, Philadelphia. 1996; 14(3):317-22.

[5] Neville BW, Damm DD, Allen CM. Bouquot J E. Patologia Oral & Maxilofacial. 2 Ed. Rio de Janeiro: Guanabara Koogan. 2004

[6] Borela PV, *et al.* Angina de Ludwig: relato de um caso. RBM-ORL, São Paulo. 1998; 5:162-4.

[7] Dugan MJ Lazow SK, Berger JR. Thoracic empyema resunting from direct extension of Ludwig's Angina: a case eport. J Oral MaxillofacSurg, Austrália. 1998; 56(8):968-71.

[8] Peterson L. Principles of oral and maxillofacial surgery. 2 ed. Canadá : BC decker. 2004.

[9] Freire Filho FWV, *et al.* F. Angina de Ludwig: relato de caso. Rev Bras Cir Periodontia, Presidente Prudente. 2003; 1(3):190-6.

[10] Marcato RA. Angina de Ludwig odontogênica: Uma análise propesctiva de nove casos consecutivos, Londrina. 2014

[11] Kurien M, *et al.* Ludwig`s angina. Clinical Otolaryngology and Allied Sciences. 1997; 22:263-65.

[12] Leite Segundo AV, *et al.* Angina de Ludwig decorrente de exodontia de molares inferiores: relato de caso clinico. Rev. Cir. Traumatologia Buco-Maxilo-Fac.2006; 6(6):23-28.

[13] Graziani M. Cirurgia Buco-Maxilo-Facial. 7 ed. Rio de Janeiro: Guanabara Koogan. 1986.