

Journal of Surgical and Clinical Dentistry

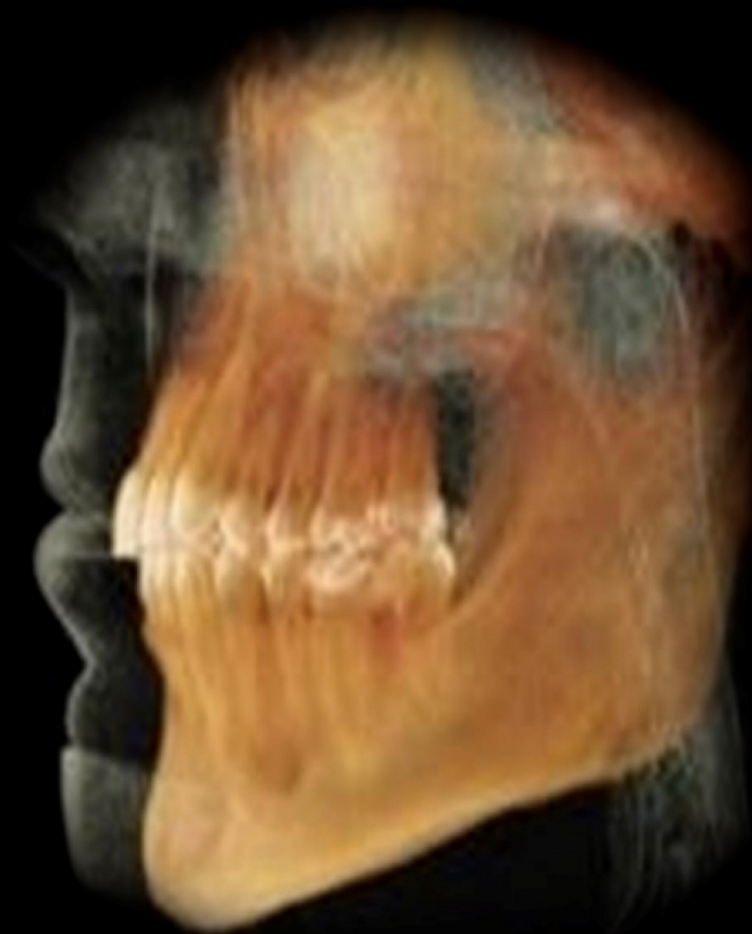
Online ISSN 2358-0356

JSCD

9(1)

April / June

2016



Title: Journal of Surgical and Clinical Dentistry

Short title: J. Surg. Clin. Dent.

Abbreviation: JSCD

Publisher: Master Editora

Periodicity: Quarterly

Indexed: Latindex, Google Scholar, EBSCO host

Start: April, 2014

Editor-in-Chief:

Prof. Dr. Mário dos Anjos Neto Filho [MSc; Dr]

*The **Journal of Surgical and Clinical Dentistry - JSCD** is an editorial product of the **Master Publisher** aimed at disseminating scientific articles only in electronic media, indexed in Latindex, Google Scholar and EBSCO host database.*

*All articles published were formally authorized by the authors and are your sole responsibility. The opinions expressed by the authors of the published articles do not necessarily correspond to the opinions of **Master Publisher**, the **JSCD** and/or its editorial board.*



Master Editora

The Brazilians open access Journals

Dear Researcher,

*We have the great pleasure to entry the ninth edition, volume one, of the **Journal of Surgical and Clinical Dentistry - JSCD**.*

*The **Master Publisher** and the **JSCD** are very grateful to the authors of the articles that brighten this edition of the invaluable collaboration, by immediately accepted our invitation and for the trust placed in this project.*

*The **JSCD** is one of the early open access Journal in Brazil, representing the materialization of the lofty ideals of **Master Publisher** about the broad and unrestricted dissemination of scientific knowledge produced by the Health Sciences.*

*Authors of scientific articles that are interested in the scope of **JSCD**, send your manuscripts for consideration of our editorial board!*

Our tenth edition will be available in July, 2016!

Happy reading!

Mário dos Anjos Neto Filho
Editor-in-Chief JSCD

CASE REPORT

CORRECTION OF SMILE THROUGH MULTIDISCIPLINARY APPROACH

LUCIANE CAVALHEIRO DA **SILVA**, RAFAELA DE FREITAS DA **SILVA**, DAYLA THIEMI **HIGASHI**, VERUSKA DE JOÃO MALHEIROS **PFAU**, EDUARDO AUGUSTO **PFAU** 05

LITERATURE REVIEW

ODONTOMAS: LITERATURE REVIEW

TATIANE MARTINS DE MATOS DOS SANTOS MORAES, ORLANDO IZOLANI NETO 12

CORRECTION OF SMILE THROUGH MULTIDISCIPLINARY APPROACH

LUCIANE CAVALHEIRO DA SILVA¹, RAFAELA DE FREITAS DA SILVA^{1*}, DAYLA THIEMI HIGASHI², VERUSKA DE JOÃO MALHEIROS PFAU³, EDUARDO AUGUSTO PFAU^{4*}

1. Dental surgeon from the University Paranaense at UNIPAR- Umuarama - PR; 2. Dental Surgeon. Master by UEL. Dentistry Course docent at the University Paranaense - UNIPAR- Umuarama- PR; 3. Dental surgeon. Master by USP. Dentistry Course docent at the University Paranaense - UNIPAR - Umuarama- PR; 4. Dental surgeon. Doctor in Implantology by Faculty São Leopoldo Mandic - Campinas SP. Dentistry Course docent at the University Paranaense UNIPAR- Umuarama- PR.

* Av. Angelo Moreira da Fonseca 5651, zone 1A, Umuarama, Paraná, Brazil. ZIP CODE: 87504-050. epfau@unipar.br

Received: 02/11/2016. Accepted: 04/07/2016

ABSTRACT

The desire for a beautiful smile has been increasingly growing in our society. Therefore, dental surgeons are required to be able to perform procedures aiming at the combination of aesthetic desire with the functionality and harmony of the dentofacial structure. Focusing on a multidisciplinary planning, the present study aimed at the implementation of a rehabilitation treatment to fix interdental spaces that were causing aesthetic dissatisfaction to the patient. To this end, the Digital Smile Design (DSD) was used. It enables an integrated diagnosis according to functional, aesthetic, and emotional needs of the patient and assists the periodontal surgery planning in order to enable a harmonious gingival contour. The treatment was initiated with the flapless surgery, which consists in increasing the clinical crown without flap elevation. As this procedure is minimally invasive, it enables a reduction in surgical time and postoperative discomfort. The direct technique with composite resin and the palatal guide were used to close the diastema. This procedure ensures excellent aesthetic results and presents low cost and reversibility. It is concluded that due to prior understanding determined by the DSD, aesthetic treatments involving periodontal surgeries and dental reconstructions may be performed with a higher level of safety.

KEYWORDS: Virtual planinng, periodontal surgery, composite resin, dental aesthetics

1. INTRODUCTION

The demand for a beautiful and aesthetic smile is growing towards modern society and this fact has required qualification of professionals to remedy these concerns of patients. In addition to the major technical and scientific advances regarding the development of dental materials that allow better resolution of cases involving aesthetic areas¹, the participation of patients in the development of own aesthetic dental planning has

been increasingly used in the routine of specialized clinics.

This recent form of dental planning and interpersonal communication have been developed from the incorporation of the use of digital cameras, which allow taken extra and intraoral photographs. Thus, the dental aesthetic planning became more discerning and individual, respecting the patient's wishes.

The method known as Digital Smile Design (DSD) is currently the form of dental plan that uses manipulation of digital images obtained from the patient in programs available on computers, for example, PowerPoint® or a software called Keynote®. Thus, using this methodology, it is possible to realize a digital drawing smile, which may be presented to the patient prior to the surgical implement and the possible solutions involving dental reconstructions and even periodontal surgery, to facilitate the understanding of the proposed planning and guiding laboratory procedures².

When patients seek for treatments aimed at improving the smile, the dentist must be aware and prepared to evaluate several factors crucial for planning. In addition to the intraoral examination designed to assess basic principles restricted to the dental structure and adjacent gingival tissues such as color, shape, size, texture and brightness, key items for the composition of a harmonious smile³, there is still the possibility of the use concepts described by visagism.

The visagism has been used in dentistry as an auxiliary tool in the DSD method, and consists of a methodology that seeks the visual balance between: the design of the final smile planned, the shape of the face and the psycho-behavioral aspects of the patient, thus preparing an image that reflects the characteristics of the type of personality with facial format⁴.

With regard to the smiling morphology presented by the dental alignment, the presence of interdental spaces called the diastema observed in the region of the upper incisors is a frequent source of dissatisfaction reported by

the patients. Various rehabilitation treatments may be adopted in order to eliminate this problem, thereby ensuring improvement of dental and cosmetic function, causing a positive social and personal impact. Among the restorative procedures, the direct technique with composite resin, currently occupies a prominent place because of aesthetic ability and longevity presented⁵, in addition to being more affordable when compared to materials used in the indirect technique.

The techniques developed for diastema closure are carried out through restorative procedures, direct or indirect, and should be well executed. This restorative procedure aims to increase the dental proportions in order to close the present gaps between the teeth in the smile area. The DSD and visagism are fundamental tools for the success of this type of treatment.

There is often the need for periodontal surgery aimed at restoring the biological distances and even a new design of the dental clinic crown for best smile planning⁶. Often this surgical procedure is viewed by patients as painful and uncomfortable; usually due to folding flaps for access to bone tissue and the discomfort caused by suture. However, in specific cases, the periodontal procedure can be achieved through surgeries that do not involve the elevation of the flap, providing a greater postoperative comfort⁷.

These operations increase call flapless crown, are suitable for fine or intermediate periodontal biotypes and aimed at the removal of the bone with the use of rotating instruments (tip cylindrical diamond top plan Sorensen® No. KG 2173, known as cut end) and manuals as periodontal and micro chisels curette, with the access via the gingival sulcus⁸.

Thus, the purpose of this article is to report a case of aesthetic dissatisfaction because of the presence of diastema, addressing the rehabilitation treatment from their planning by the method Digital Smile Design (DSD), the completion of periodontal plastic surgery flapless until closing diastema through direct technical composite resin.

2. CASE REPORT

Patient A. C. leukoderma, 30, female, attended the dental clinic at the University Paranaense - Unipar, campus Umuarama, Paraná, reporting dissatisfaction with the interproximal spaces and fractures in the incisal edges of the maxillary anterior teeth (Figure 1).

On examination, the patient showed no systemic change, however, the intraoral examination, it was found carious lesions in some dental and gingivitis elements. Thus, the execution of the adaptation of procedures oral environment was necessary to subsequently correct the aesthetic needs of the patient.

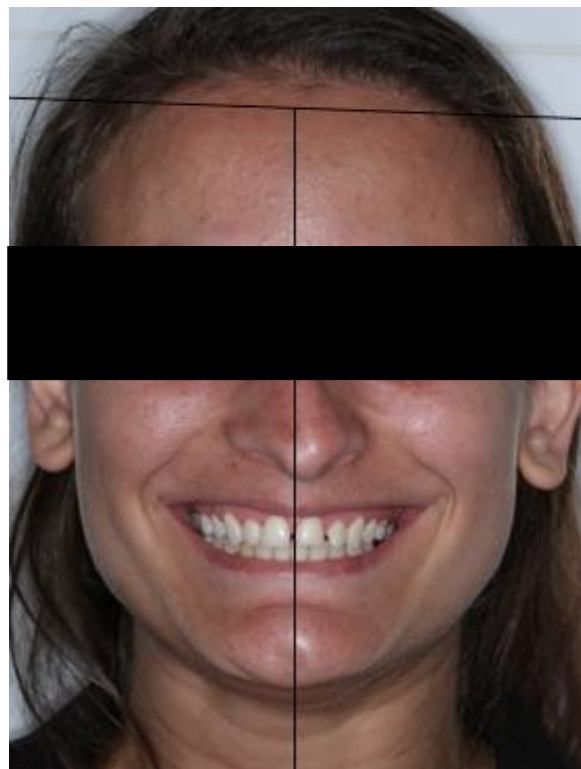

Figure 1. Initial smiling patient with the opening lines of the DSD.

After performing the oral hygiene instruction and final restorations on teeth compromised by decay, were performed intra and extraoral photographs for aesthetic planning smile. a molding was conducted in alginate (Hydrogun-Zhermack®, Badia Polesine (Rovigo) - Italy), with the aid of metal trays size S3 and I3, for making the study models. The photographs were entered in Key-note® program which was performed smile digital planning called DSD (Digital Smile Design). This procedure involves inserting paths, seeking symmetry and a new smile format (Figure 2).

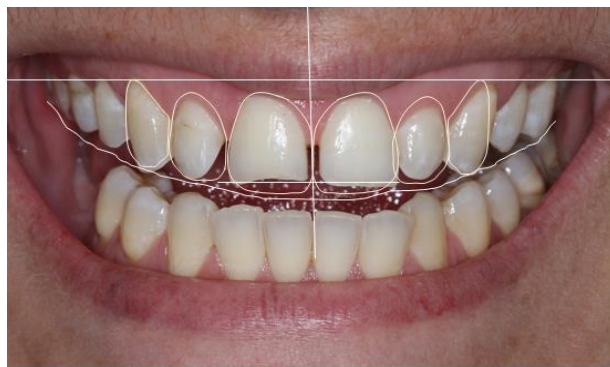

Figure 2. Digital planning with input lines to determine the new design smile.

Through this design, it can be seen the need for an augmentation surgery clinical crown and also to new proportions of the tooth digitally developed, can achieve

better communication with the prosthetic laboratory. This digital form of communication between the dentist and the prosthetic, allowed a better understanding of the lab for making the diagnostic waxing on the study models, respecting the dental morphological limits previously determined in the DSD.

With the diagnostic waxing ready, it was made a condensation silicone guide (Zetalabor-Zhermack®, Badia Polesine (Rovigo) - Italy) in order to perform the mock up resin Bis-Acrl® (Protemp 3M / ESPE Express®, Seefeld - Germany) color A2, allowing a preview of the proposed treatment (Figure 3 and 4).

Finish this step with informed consent for the patient, it was decided by periodontal surgical treatment for smile correction and then the healing period, the completion of diastema closures with direct facets in composite, taking into consideration the effectiveness, treatment time, possibility of reversal and costs.

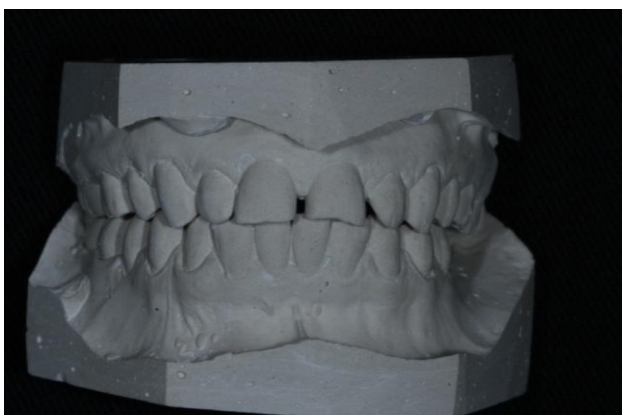

Figure 3. Model of study for making the diagnosis waxing and mock-up.

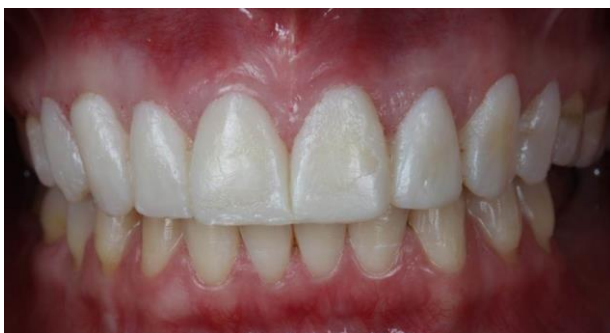

Figure 4. Mock-up into position.

For diagnostic purposes a periodontal examination was performed. This examination allowed to detect the periodontal health condition, and identified the location of the enamel-cementum junction. Before the surgery the increase of the clinical crown, the mock-up has been reinserted, such as surgical guide for realization of the clinical crown augmentation surgery.

We started the surgical procedure with antisepsis of the face (10% povidone and rinses with chlorhexidine

gluconate 0.12% for 30 seconds). Then, there was anesthesia of the infraorbital nerve and middle superior alveolar nerve bilaterally with interpapillary complementation buccal and palatal using anesthetic mepivacaine 2% + epinephrine 1: 100,000.

With the scalpel blade 15c rounded up the mock-up of the first premolar right to left first premolar, with the blade facing apically forming an internal bevel (Figure 5).

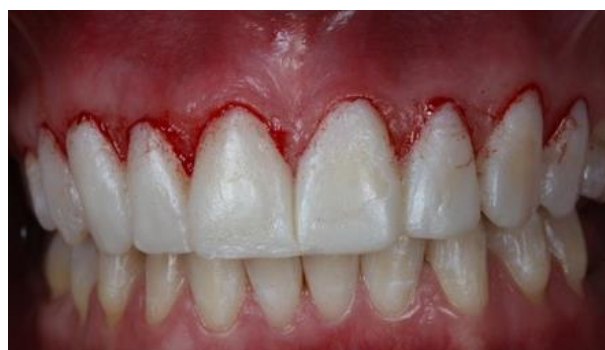

Figure 5. Mock-up used as a surgical guide and incision internal bevel.

Then, he removed the bis-Acrl resin, and the collar was removed following the contour performed by the first incision, with a curette McCall 13-14 (Figure 6).

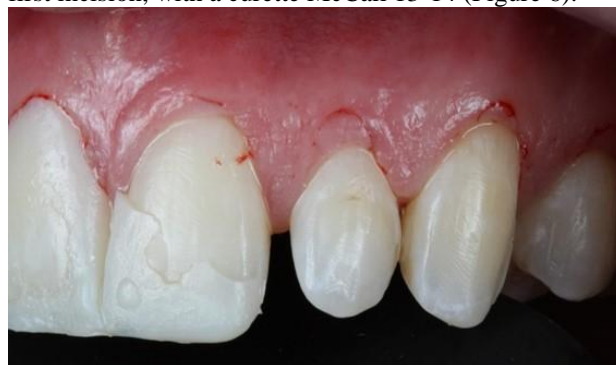

Figure 6. Mock-up removal and collar display to be removed.

With the graduated periodontal probe Goldman Fox Williams found that the distance between the gingival margin and bone crest of 2 mm, indicating the need for osteotomy (Figure 7).

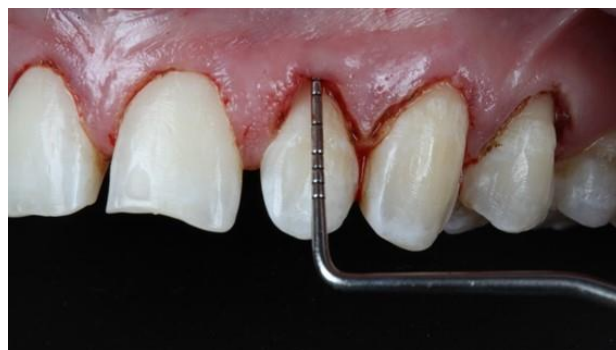

Figure 7. Collar Worker removed and verification of biological space, even with 2mm.

For better comfort during and after the procedure, we opted for the non-lifting of the flap technique, known as "flapless". The osteotomy was performed with a micro chisel straight Ochsenbein in. 1 (Figure 8).

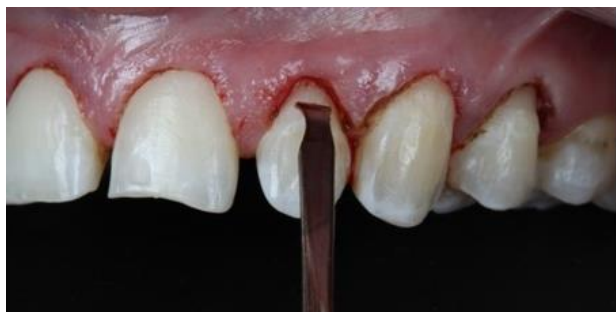

Figure 8. Restoring the biological space with micro via chisels gingival sulcus.

Subsequently a bone in-va survey was conducted in finding a distance of 3mm-VA between the gingival margin and bone crest (Figure 9).

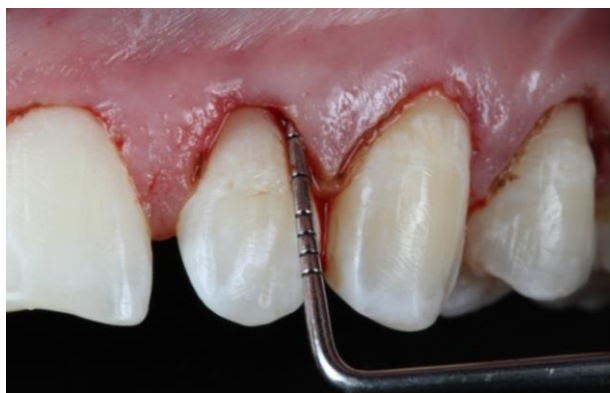

Figure 9. New survey for confirmation of 3mm of biological space.

The patient received guidance on post-operative care, recommended mouthwash with chlorhexidine digluconate 0.12% twice a day for seven days, in addition to analgesia was prescribed Acetaminophen 750mg every 6 hours, for three days and nimesulide 100mg, every 12 hours for three days.

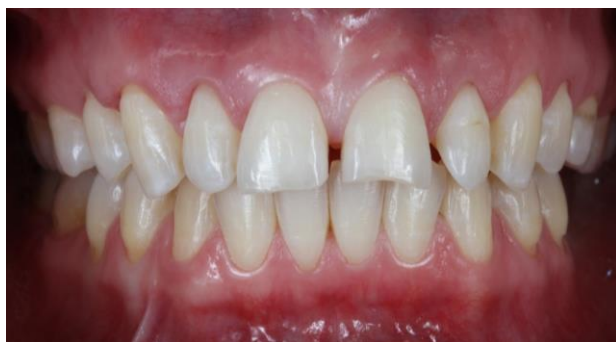

Figure 10. After 40 days of surgery.

Postoperative control was performed after 15 days for clinical examination of the surgical area. It was ob-

served after 40 days, good healing of the gingival tissue with harmonic and satisfactory outline (Figure 10). The patient reported no postoperative symptoms and showed satisfaction with the outcome.

After 6 months of the periodontal surgery, gave the start to the aesthetic of the smile reestablishing the direct technique with composite resin (Filtek Z350 XT 3M / ESPE®, St. Paul, Minnesota, USA) and use the palatal guide made from silicone condensation ((Zetalabor-Zhermack®, Badia Polesine (Rovigo), Italy). Initially, there was prophylaxis with pumice and water with rubber cup aid. then the color selection has been made, especially color A2 (A2 + A2 body enamel- Filtek Z350 XT 3M / ESPE®, St. Paul, Minnesota, USA).

The infiltrative anesthesia was performed in the region of the first premolar bilaterally. Then it was positioned absolute isolation by the modified technique, known as "canoe". The tooth surface was conditioned with phosphoric acid at 37% for 30 seconds, followed by washing the same and dry with paper towels. The adhesive system used was 2 single bond (3M / ESPE®, St. Paul, Minnesota, USA) and the first layer applied microbrush and solubilized with compressed air. Then a second layer was applied, solubilized and photopolymerized for 20 seconds.

The palatine guide was positioned to facilitate insertion of the first layers of composite A2E (Filtek Z350 XT 3M / ESPE®, St. Paul, Minnesota, USA), responsible for form the palatal face of the teeth to be restored (Figure 11).

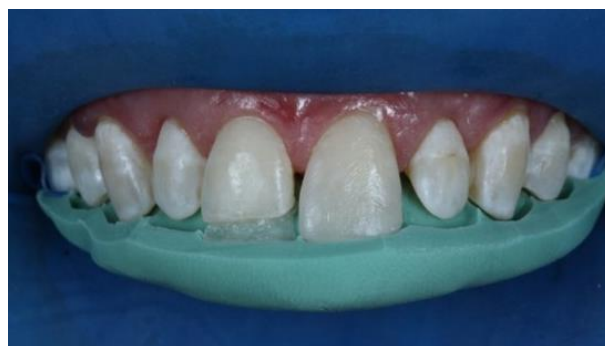

Figure 11. absolute isolation of the canoe type; palatal guide in position assisting in the reconstruction of teeth.

After determination of the palatal limits, the guide was removed and began laminating resin increases in maxillary central incisors. In the cervical third by dressing bular, applied to B3B resin, in the middle third A2D, and A2E incisal third, each increment being light cured for 40 seconds. He ended up with a final increase of A2E resin. This process was repeated in all upper-anterior teeth and the first premolars.

Upon completion of the restoration, was started to occlusal adjustment, to make sure no interference remained. The finishing and polishing were carried out after a week. the sanding disks were used for finishing

(Diamondpro of FGM®, Joinville, SC-Brazil), according to their granulations for free faces.

In interproximal the number 12 scalpel blade was used next to the neck of the teeth, along with the Sof-Lex® sanding strips of 3M / ESPE®, St. Paul, Minnesota, USA). The final polishing was done with paste for polishing (Diamond Ex-cel-FGM®, Joinville, SC, Brazil) using the felt disc (Figure 12).

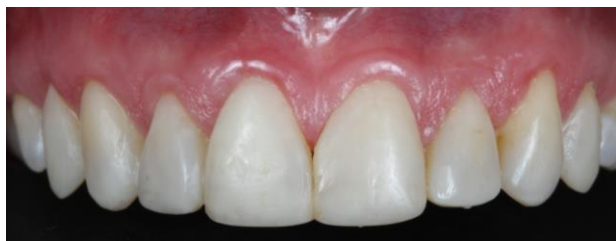

Figure 12. Final Direct restoration after polishing.

The patient was advised of the need for oral hygiene and flossing. The rhetorician us proservation the case were made men-sally and a new radiography control was performed after 6 months to certify that there was no aggression to supporting tissues and the same stable (Figure 13 and 14).

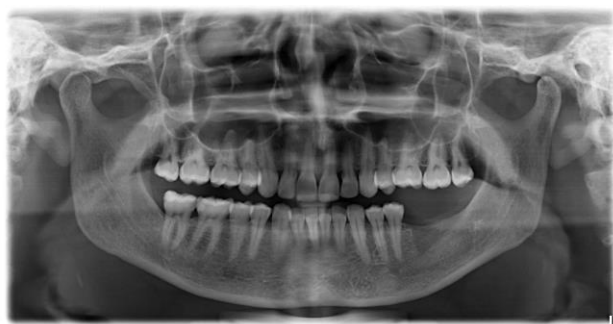

Figure 13. Final panoramic radiograph.

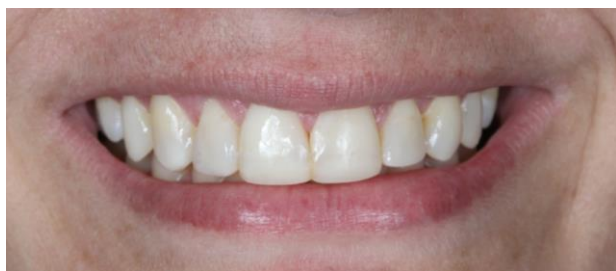

Figure 14. Final smiling.

3. DISCUSSION

The presence of interproximal spaces, known as diastema, can appear anywhere in the arcades, which is one of the main common aesthetic complaints⁹, as these inter-dental spaces discourages the beauty and dentofacial harmony and can contribute negatively welfare and social relations of the individual¹⁰. This interference in facial aesthetic results from the process of formation of

craniofacial structure, which is determined to make up skeletal-sition, characteristic tooth and muscle of each person⁹.

The formation of diastema is the result of an imbalance in the size and shape of the teeth and dental arches, limiting a correct fit of the teeth¹¹. Its etiology is associated with congenital or acquired factors such as muscle imbalance of the oral cavity, structure abnormalities jaw and tooth, malocclusion, crowding¹² teeth missing due to caries or periodontal problems, prominent labial brakes, dentoalveolar discrepancies, pathological conditions, harmful habits and heredity¹³, which is the main cause of the case.

The treatment for diastema is aimed at its closure and may be through veneers, porcelain crowns, orthodontic treatment, restorations with composite resin only, or also, in some cases, there is need to involve the closure composite resin with periodontal surgery as gingivectomy / gingivoplasty to lengthen the crown of teeth¹⁴, being an indispensable multidisciplinary planning.

The interrelationship of Operative Dentistry and Periodontology are fundamental to an aesthetic harmony, especially for healthy maintenance of support structures. This interdisciplinary planning requires knowledge of dental and periodontal anatomy, since, in many situations, previous periodontal conduct the restorative procedure are necessary to restore the biological properties of periodontal¹⁵.

According Zanetti *et al.* (2007)¹⁶, a correct diagnosis is achieved thanks to the multidisciplinary integration which allows results with greater predictability and security, but only technical knowledge is insufficient for a complete treatment success and patient satisfaction, because the smile did not totals only dental formats and sizes, but a feature of harmony, beauty and personality.

A new vision within the current aesthetic known as cosmetology, gained space in the dental plan. Its purpose is to customize the smile with harmony, associating behavioral characteristics with the face size and shape of the teeth in which reflects naturalness and individuality^{4,17}. According Hallawell (2009)¹⁸ there are four types of temperaments and each with a dental format: choleric designated strong and rectangular teeth, Sanguine being dynamic and triangular teeth, melancholic being sensitive and oval and phlegmatic peaceful teeth with square teeth, and this more probability of the presence of diastema. The patient, according to its characteristics, was classified as peaceful and sensitive.

This concept provides an aesthetic smile together with their psychosocial characteristics, nullifying the sensation to the patient that this proposed smile belongs to you not¹⁹. This can be remedied, still in the early planning in which the patient gets a preview of treatment end by photographs. Digital images are auxiliary methods in planning that demonstrate clearly and objectively,

the necessary changes in average patient agreement and its professional, and facilitate communication with the laboratory^{20,21}.

Photographs can be worked in computer programs using a tool known as DSD (Digital Smile Design), in which this program contributes to the virtual dental planning. Consists of inserting lines into digital photos pa-aware to provide better understanding of the case and a comprehensive view of treatment and may be essential also in the surgical periodontal-planning²². This protocol requires no special equipment and can use the software programs, Keynote or PowerPoint, making it an affordable and reliable tool for the comprehensive treatment plan and multidisciplinary²³.

The accuracy of the DSD can be evaluated by the diagnostic wax and the mock-up, this being an intraoral test done with bis-Acrl and a silicon wall². The diagnostic wax is the restorer test in the study model, and aims to rebuild the worn portion of the teeth, guiding the new smile format²⁴. The mock-up is the restorer intraoral test with chemically activated resins. This step allows the patient a pre-idealization of income and their participation in the final decisions, above all, it helps in periodontal planning serving as a guide for the surgical procedure²⁵ where, with the mock-up in place, the increase in clinical crown can be done with greater security, providing correct alignment for gingival harmony. The use of this work protocol offers a treatment with greater predictability and is indispensable in a multidisciplinary planning²⁶.

View in the present clinical case the need to increase clinical crown in order to harmonize the gingival margin in relation to the lip, and increase tooth structure allowing the closure of diastema²⁷.

The increase in clinical crown is a more surgical procedures used by dentists in order to preserve the biological space²⁸, and includes the excision of soft tissue by gingivectomy, and when the osteotomy bone removal is required²⁹.

With a view to greater comfort and better postoperative for the patient, the technique of choice was increased flapless clinical crown. This procedure is well indicated on thin periodontium, dispensing lifting a total retail and performing the osteotomy with hand tools, such as micro-chisels, via gingival sulcus³⁰.

The flapless surgery enables the maintenance of the periosteum enhancing the healing process and increased vascularization reducing postoperative inflammation. Thus bone resorption is reduced contributing to a better healing⁷.

The extension osteotomy, where crowns or veneers are scheduled is determined by the future prosthetic margin position which must coincide with the gingival margin³⁰. The new drilling after the osteotomy is essential in order to confirm the biological distance according

Rissato & Trentin (2012)²⁹, should be 3 to 4 mm from the preparation completion to the alveolar ridge, in order to conserve the integrity of the structures that comprise the biological space.

We agree with Cimo *et al.* (2013)²⁸, when we say that, according to studies, up to six months after surgery, the gingival margin can vary in position. Therefore, one must observe the settling time that varies from 3 to 6 months, to perform rehabilitation with an aesthetic restorative materials. Above all, there are risks of the union dentogingival destabilize if the restorative treatment is performed prior to the recommended healing period³¹.

For aesthetic finish of the case, the closing of the diastema option was the direct technique with composite resin, which is a more conservative procedure, simple and allows reversibility¹¹. This methodology today occupies a prominent place due to its advantages such as color stability and surface smoothness⁵ and also to be economically less expensive when compared to indirect techniques.

The composite resins have improved a lot as its color stability and bonding strength, so its advantages as reversibility, financial cost and clinical time reduced³², made us to consider this direct technique as a great option to treatment aesthetic rehabilitation.

Follow up is required for these cases, involving changes in dental morphology, because we believe that one should not dissociate it the full treatment, since during the adaptation phase, there may be a need for small occlusal adjustments and these periodic evaluations are Essential to the periodontal health maintenance and to ensure the results obtained.

4. CONCLUSION

Despite the smile correction pose a major challenge for dentistry, considering the functional, aesthetic and psychological impact on patients, the multidisciplinary action by integrating procedures such as DSD in dental routine has been shown to be valid. Thus, aesthetic treatments involving periodontal surgery and dental reconstructions, can be performed with greater security due to the previous agreement given by DSD.

REFERENCES

- [1] Kakehashi Reges RV, et al. Proporção áurea: um guia do tratamento estético. JBD - Jornal Brasileiro de Dentística e Estética, Curitiba, 2002; 1(4):292-95.
- [2] Coachman C, Calamita M, Schayder A. Digital smile design: uma ferramenta para planejamento e comunicação em odontologia estética. Dicas, 2012; 1(2):36-41.
- [3] Netto L, Reis R. restabelecimento estético-funcional de dentes ântero-superiores com rara alteração de cor e forma. relato de caso clínico. Dentística online. 2011; 10(20). [Access 30 jun. 2015] Available in: <http://coral.ufsm.br/dentisticaonline/1007.pdf>.

- [4] Paolucci B, Gürel G. Aplicação clínica do Visagismo. *PróteseNews*, 2015; 2(3):19-37.
- [5] Pfeifer JMGA, et al. Conceitos de estética envolvidos no fechamento de diastemas e reanatomização de dentes anteriores com resina composta. *JBD – Revista Ibero-americana de odontologia Estética e Dentística*, 2004; 3(10):122-31.
- [6] Kao RT, et al. Thick vs. Thin gingival Biotypes: a key Determinant in Treatment Planning for Dental Implants. *Cda journal*, 2008; 36(3):193-98.
- [7] Corrêa BB, et al. Correção de sorriso gengival com osteotomia sem retalho: previsibilidade com o mínimo de morbidade. *Dental Press Implantology*, 2014; 8(2):64-69.
- [8] Joly JC, Carvalho PFM, Silva RC. *Perio-Implantodontia Estética*. 1 ed. São Paulo: Quintessence, 2015; 495 p.
- [9] Canuto MSB, et al. Análise comparativa entre presença de diastemas e tipos faciais. *Rev CEFAC*, São Paulo, 2006; 8(2):162-70.
- [10] Almeida RR et al. Diastema interincisivos centrais superiores: quando e como intervir? *R Dental Press Ortodon Ortop Facial*, 2004; 9(3):137-56.
- [11] Tomás ARC. Conceitos de estética: Encerramento de diastemas com resinas compostas no sector anterior. 2011. 69 f, Monografia (Mestrado em Medicina Dentária) – Universidade Fernando Pessoa, Porto. 2011.
- [12] Azevedo FF. Etiologia, tratamento e estabilidade dos diastemas. 2010. 46 f, Monografia (Especialização em Ortodontia) – FUNORTE/SOEBRÁS, Anápolis. 2010.
- [13] Estaregue F. Fechamento de diastemas. 2004. 30 f, Monografia (Especialização em Dentística Restauradora) – Universidade Estadual de Campinas, Piracicaba. 2004.
- [14] Kajewski AD. Fechamento de diastema e correção de lateral conóide utilizando resina composta direta: Relato de caso. 2012. 39 f, Monografia (Especialização em Dentística) – Instituto Latino Americano de Pesquisa e Ensino Odontológico, Curitiba. 2012.
- [15] Oliveira DA, et al. Inter-relação da periodontia e outras especialidades odontológicas – Revisão de literatura. *Braz J Periodontol*, 2012; 22(3):25-29.
- [16] Zanetti GR, et al. Integração orto-perio-prótese para correção de assimetria gengival – Relato de caso. *R Dental Press Estét*, 2007; 4(4):50-60.
- [17] Kao CMS, et al. Visagismo na odontologia: A personalização do sorriso. *Revista odontológica de Araçatuba*, 2014; 35(2):67-70.
- [18] Hallawell P. *Visagismo integrado: identidade, estilo e beleza*. São Paulo: Senac. 2009.
- [19] Silva IT. Os desafios da odontologia estética DSD – como projetar o sorriso ideal. 2013. 45 f, Trabalho de Conclusão de Curso (Graduação em Odontologia) – Universidade Federal de Santa Catarina, Florianópolis. 2013.
- [20] Xavier TD. Planejamento estético em dentística restauradora e reabilitadora: Revisão de literatura. 2013. 42f, Trabalho de Conclusão de Curso (Graduação em Odontologia) – Universidade Estadual de Londrina, Londrina. 2013.
- [21] Shibasaki DN. et al. Recursos contemporâneos do planejamento estético integrado. *Revista Bahiana de Odontologia*, 2013; 4(2): 147-57.
- [22] Ruhmann NL. et al. Aesthetic rehabilitation of the “gummy smile” associated to virtual planning with “digital smile design” – DSD. *Journal of Surgical and Clinical Dentistry – JSCD*, 2014; 1(1):5-9.
- [23] Pinto DCS. et al. Desenho digital do sorriso – descrição de uma nova técnica. *Revista Gestão & Saúde*, 2014; 11: 01-09.
- [24] Meirelles L, Bavia PF, Vilanova LS. R. Aplicações clínicas do encerramento diagnóstico na reabilitação oral – uma revisão de literatura. *R da Faculdade de Odontologia de Lins/Unimep*, 2013; 23(1):20-25.
- [25] Paiva AO. et al. Enceramento diagnóstico e mock-up no planejamento das correções de sorrisos gengivais. *PerioNews*, 2013; 7(5):453-59.
- [26] Warmling OG. Mock-up – ensaio restaurador. 2014. 38 f, Trabalho de Conclusão de Curso (Graduação em Odontologia) – Universidade Federal de Santa Catarina, Florianópolis. 2014.
- [27] Souza SJB, et al. Cirurgia plástica periodontal para correção de sorriso gengival associada à restaurações em resina composta: Relato de caso clínico. *Rev Odontol Bras Central*, 2010; 19(51):362-66.
- [28] Cimões, R, Gusmão ES, Donos N. *Manual Prático para Cirurgia Periodontal e Periimplantar*. 1 ed. São Paulo: Napoleão. 2013.
- [29] Rissato M, Trentin MS. Aumento de coroa clínica para restabelecimento das distâncias biológicas com finalidade restauradora – Revisão de literatura. *RFO*, 2012; 17(2):234-39.
- [30] Carvalho PFM, Silva RC, Joly JC. Aumento de coroa clínica estético sem retalho: uma nova alternativa terapêutica. *Associação Paulista de Cirurgias Dentistas*, 2010; 26-33.
- [31] Rolo T, et al. Cirurgia de aumento de coroa clínica. 2014. [access 21 set. 2015] Available in: http://clinicadeesgueira.com/wp-content/uploads/2014/09/artigo_cirurgia_de_aumento_de_coroa_clinica.
- [32] Castro MAM, et al. Diastemas: reestablishment of an attractive smile. *RGO - Rev Gaúcha Odontol*, 2010; 58(2):253-56.