

ASSISTED SEDATION AS AN ALTERNATIVE FOR NON-COLLABORATIVE CHILDREN: CASE REPORT

KARLINE KATIUSCIA TAKEMOTO^{1*}, TEREZA CRISTINA ROSCHEL GIFFONI², LUCIMARA CHELES DA SILVA FRANZIN³, ERMELINDA MATSUURA⁴, PATRICIA SARAM PROGIANTE⁵, SUZANA GOYA⁶

1. Undergraduate Student in Dentistry, UNINGÁ; 2. Professor of Dentistry at the UNINGÁ; 3. Dentist, PhD by PUC-PR, Professor of Dentistry at the UNINGÁ; 4. Master in Integrated Dentistry by UEM, Professor of Dentistry at the UNINGÁ; 5. Dentistry, Post-Doctor in Health Sciences by FOB-USP). Professor of Dentistry at the UNINGÁ; 6. Dentistry, PhD in Applied and Pure Sciences - Collective Health by FOB-USP, Professor of Dentistry at the UNINGÁ.

* Mamborê Street, 1634, Downtown, Campo Mourão, Paraná, Brazil . ZIP CODE: 87302140. karlinetakemoto20@hotmail.com

Received: 07/29/2016. Accepted: 10/10/2016

ABSTRACT

Anxiety and fear are factors that can harm dental practice in adults and children. There are children who are anxious and afraid and due to the fact that they cannot overcome this fear they are classified as non-collaborative. If there is no cooperation even after using all handling techniques and physical constraint for the treatment of these children, pharmacological techniques such as assisted sedation are used. With a good indication, careful planning and skill of the dentist professional, it is a technique with a good clinical outcome and that prevents psychological trauma. It is presented in this report of clinical case, the use of deep sedation also named assisted sedation, as a second treatment option, after the rejection of conventional treatment techniques for the 4 year-old child in 10 clinical sessions management with the pedodontist.

KEYWORDS: Sedation; analgesia; anxiety; dentistry.

1. INTRODUCTION

Dental practice was and still is classified by a portion of the population as an unpleasant experience. According to Malamed (1996)¹ the dental consultation was considered the second greatest fear of the population described as an unpleasant experience in which there is pain, discomfort, noises and strong odors.

Therefore some patients will present the sensation of discomfort or fear during dental care². In dentistry this fear can be transient or not being classified in objective fear when the threat is real or subjective when it is induced or imaginary³.

Concomitantly to fear there is anxiety that is considered a psychic state of apprehension or fear caused by anticipation of an unpleasant or dangerous situation and is present in non-collaborative children to dental treatment, significantly altering the physical and psychological state of the patient⁴.

In pediatric dentistry it is verified that the behavior of the child during dental care is essential for the success of non-pharmacological clinical treatment⁵. The caregiver

should be attentive to the child's reactions before, during and after clinical care to see if they are positive or negative in order to avoid causing trauma⁶.

There are several techniques used to control infant behavior during dental treatment that may be known as management techniques. Associated with the linguistic domain, child management techniques are procedures that aim to prevent and alleviate fear and anxiety, establish good communication and educate the patient by encouraging them to cooperate during dental treatment⁷. Pediatric dentistry may be pharmacological and non-pharmacological techniques⁸.

The non-pharmacological techniques have the purpose of managing the child's behavior to provide safety and tranquility to the child and their parents⁹ and are: Nonverbal communication, physical touch, talk-show-doing, desensitization, modeling, distraction, positive reinforcement, negative reinforcement, voice control and physical immobilization¹⁰.

In cases of intense fear and anxiety in which the child does not cooperate and management techniques are ineffective, there is a need for the use of pharmacological techniques in order to obtain the maximum therapeutic result but with the least adverse reactions to the child. Conscious inhalation sedation and general anesthesia are the most commonly used pharmacological techniques in pediatric dentistry¹¹.

2. LITERATURE REVIEW

According to Macdonald (2011)¹² there is a classification by the American Academy of Pediatric Dentistry (AAPD) for sedation levels that are: minimal sedation, moderate sedation, deep sedation.

Minimal Sedation is defined as an altered or depressed state of the patient's level of consciousness caused by medications, which does not affect their ability to maintain airways and cardiovascular function independently and continuously, as well as the ability to respond appropriately, To physical stimuli and verbal command even if

cognitive functions and coordination are compromised.

In moderate sedation there is depression of drug-induced consciousness, during which the patient responds intentionally to a verbal command and / or a slight tactile stimulus. No intervention is required to keep the airway permeable and spontaneous ventilation is adequate and cardiovascular function is normal.

And deep sedation is one in which the patient is with most of his or her reflexes depressed and may be without spontaneous breathing¹².

The American Dental Association - ADA (1997) defined deep sedation and general anesthesia as being a controlled state of unconsciousness, accompanied by partial or complete loss of protective reflexes, including the ability to breathe independently and voluntarily respond to physical stimulation or verbal command, which is produced by pharmacological method, non-pharmacological or their combinations¹³.

The dentist surgeon must be able to perform conscious sedation and master the technique of choice. For sedation is used benzodiazepines that have hypnotic and sedative properties or inhalation by nitrous oxide considered a sedative agent, in cases of requiring conscious sedation of minimal or moderate level. The choice of medication, technique or the association of both without a dental office should be used responsibly and with the professional's broad knowledge of Law No. 5081 of August 24, 1966, which in article 6, item VI, Explains that the dental surgeon can apply analgesia, provided that it is proven and when its use is an effective means of treatment and resolution 51/04 of the CFO (Federal Council of Dentistry) that establishes the need for a 96-hour course to Enable the dental surgeon to apply relative analgesia or conscious sedation that will be formally trained to perform such procedure from the pharmacology, routes of administration, and recovery of the patient¹⁴.

In cases in which the professional opts for a deep sedation he should have a qualified team and only the anesthesiologist can proceed in this technique of sedation in an ambulatory or hospital environment, with monitoring equipment, because in this level of sedation the patient should be Assisted during and after the procedure and even in the case of benzodiazepine sedation, nitrous oxide inhalation or deep sedation, the use of analgesia by local anesthetics is not ruled out, responses to the use of these drugs are individual and levels are continuous, occurring with Frequency, the transition between them¹⁵. The physician prescribing or administering the medication should have the ability to recover the patient from this level or maintain it and recover it from a state of greater depression of cardiovascular and respiratory functions¹⁶.

As noted in the world literature, sedation has been used quite successfully after proper patient selection, careful and documented planning and use of the indicated technique with the aim of minimizing the psychological

trauma of a conventional treatment and maximizing the potential of Amnesia caused by sedation¹⁷.

3. CASE REPORT

A 4-year-old female child entered the dental clinic accompanied by the mother with major complaint of tooth pain due to multiple dental caries. The legal guardian, in the case of the mother, reported in the anamnesis that general health is good, with no history of childhood diseases or other types of systemic problems, did not present any type of allergic reaction to medications and local anesthesia, feeding was with Homemade food and daily oral hygiene.

After signing the clinical file, the Term of Free and Informed Commitment, authorization for use of the image was initiated clinical care.

In the extra-oral evaluation, it presented a normality pattern. In the intra-oral evaluation, the lips, cheek, tongue, hard and soft palate, lingual floor and gingiva were examined and found to be unchanged.

In the evaluation of caries risk, a diagnosis of carious lesion was made on the following elements: 51, 52, 54, 55, 61, 62, 64, 65, 74, 75, 84 and 85. Elements 53, 63, 73, 72, 71, 81, 82 and 83 are healthy (Figure 1, 2 and 3).

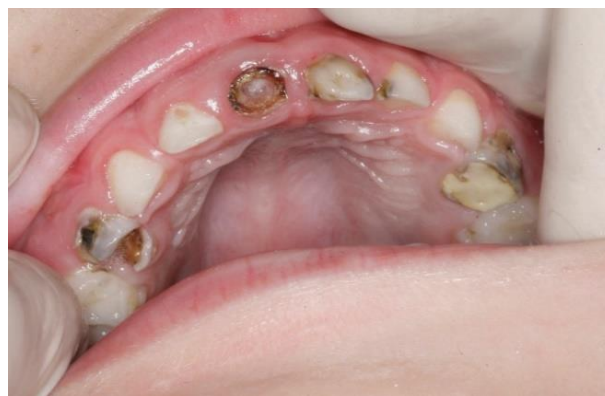

Figure 1. Intraoral frontal view with multiple carious lesions in elements 52, 54, 55, 61, 62, 64, 65 and total destruction of the crown of 51.

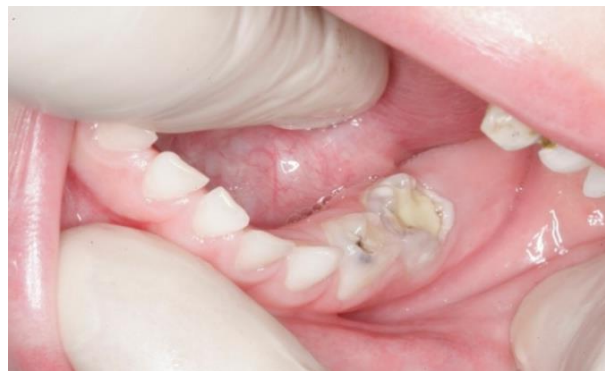

Figure 2. Intraoral view with carious lesion on elements 74 and 75 in the occlusal.

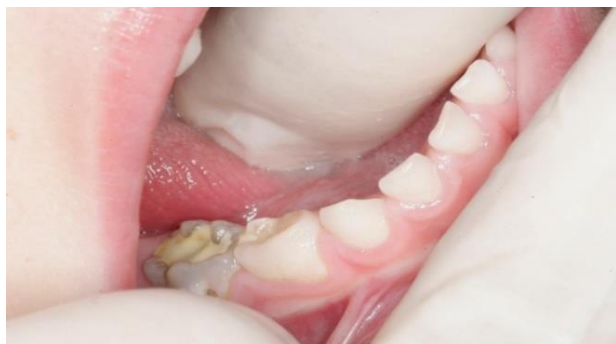

Figure 3. Intraoral view with carious lesion in elements 84 and 85 of this occlusal.

The proposed treatment plan was preventive treatment (oral hygiene instruction, prophylaxis and topical application of fluoride) and restorative treatment (adjustment of the buccal medium for later restorative treatment). Therefore, the health education for the child and the mother was initiated through oral hygiene instruction and diet recommendations with the accomplishment of management technique with child in the dental chair.

However, after 10 sessions of clinical management and the refusal of the child's collaboration in dental care, due to the child's immaturity and the clinical conditions of the mouth, all procedures were performed in an outpatient clinic with assisted sedation.

Induction for sedation and the clinical procedure started at 08:00 am and ended at 12:15 a.m., with a duration of 4 hours of clinical care.

The medications used by the anesthetist to induce analgesia were Dormonid syrup 0.5 mg per kg (1.25 mg) as pre-anesthetic medication; Fentanyl 1 to 2 mcg per kg (50 mg); Propofol 1 to 1.5 mg/ kg (70mg); Propofol in pump 100 mcg/ kg in minute (15 mL/ 1 h).

Midazolam is the benzodiazepine of choice for short-acting sedation, has a short half-life, being 2 to 4 times more potent than Diazepam. Because it is water soluble, it is painless both in intravenous and intramuscular administration.

Fentanyl is a semi-synthetic opioid with rapid onset of action is 100 times more potent than morphine, it is the opioid of choice for analgesia in short procedures. It has few cardiovascular effects, releases less histamine, but can cause stiffness of the rib cage, especially after rapid intravenous infusion that can be reversed with the use of antagonistic drugs or with muscle relaxants.

Propofol is an ultra fast acting anesthetic agent, inducing immediate sedation. Its great advantage relates to the rapid sedative effect¹⁹.

The medications given were the antibiotic Cefazoline 25 mg per kg (625 mg); corticosteroids Dexamethasone 0.1 mg per kg (2.5 mg), Ondansetron 0.1 mg per kg (2.5 mg) and analgesic Dipyron sodium 20 mg per kg EV

(500 mg) (Figure 4a And Figure 4b). Cefazolin is antibacterial cephalosporin of 1st generation; Beta-lactam; Cefazolin sodium.

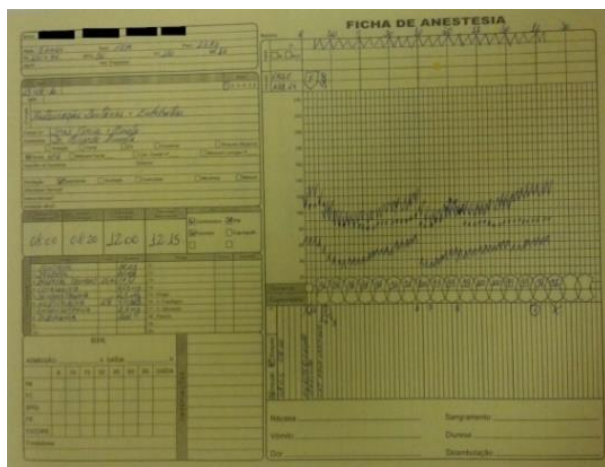
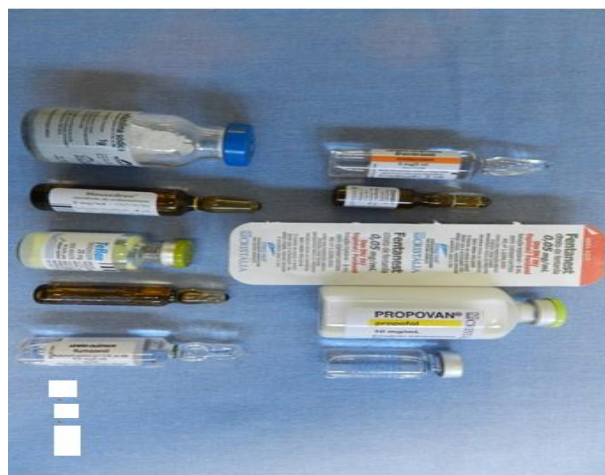

Figure 4 a. Medications used; **Figure 4b-** Anesthesia card (The operating room should be equipped with ventilatory support, multi-parameter monitor).

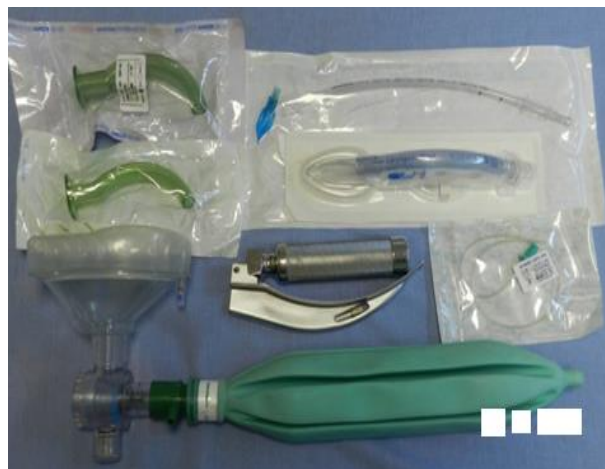

Figure 5. Ventilatory support.

Dexamethasone has potent anti-inflammatory action²⁰. Ondansetron is indicated for the control of nausea and vomiting induced by chemotherapy, radiotherapy and also indicated for the prevention and treatment of postoperative nausea and vomiting.

Dipyron has analgesic, antispasmodic and antipyretic action in Brazil, it is widely used in the treatment of mild pain, and synergism with opioids in the treatment of moderate and intense pain, and it can be used orally, venous and rectally²¹.

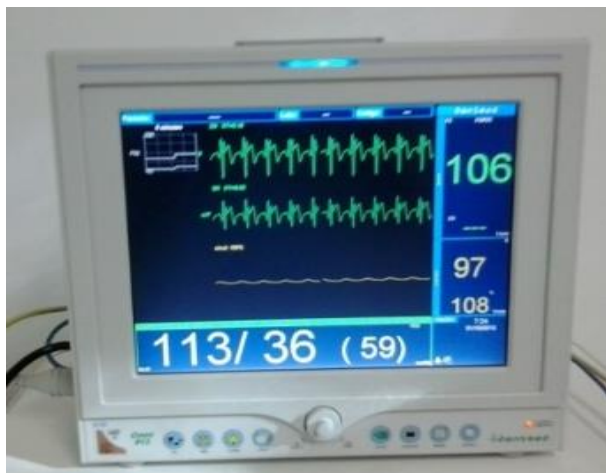


Figure 6. Multi-parameter monitor.



Figure 7. Oxygen torpedo and defibrillator for patient monitoring, induction and recovery.

After sedation, clinical care was started by performing local infiltrative anesthesia with the use of 4 tubes of the

local anesthetic Mepivacaine at 2%. After the anesthesia, the endodontics of element 51 begins and crown is made in composite resin with glass fiber pin cemented with zinc phosphate, cervical vestibule restoration in composite resin of element 52.

In element 61 there was the vestibule restoration and class IV in composite resin color A1. The element 62 received a mesial restoration in composite resin (Figure 8). As a precaution, an upper impression was made for the preparation of an apparatus if the element 51 could fracture.

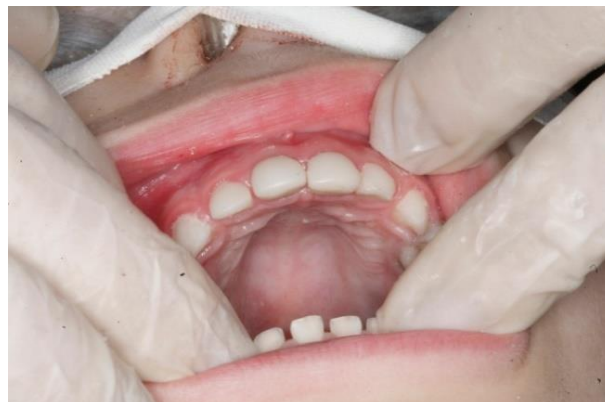

Figure 8. Frontal view after the end of treatment in the maxilla region.

In element 54, endodontics with CTZ (chloramphenicol, tetracycline, zinc oxide and eugenol) was performed, and the insertion of CIV (Glass Ionomer Cement) and restoration in composite resin and composite resin restoration element occlusal and sealant application (Figure 9).

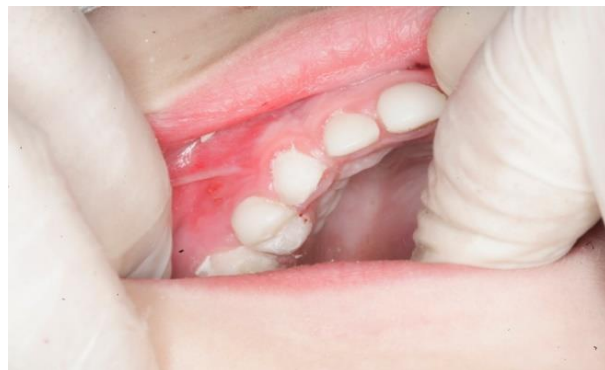

Figure 9. View of the upper right region after completion of endodontics, restorations and sealant application.

In element 64, endodontics was performed with CTZ medication and the insertion of CIV (Glass Ionomer Cement) and restoration in composite resin and then restoration of element 65 in composite resin in the occlusal and palatine and the application of sealant (Figure 10).

After the upper maxillary region was finished, treatment of the lower region with the restoration in composite resin, application of sealant in element 74 in

element 75, endodontics with CTZ medication, a guiding CIV base and restoration with composite resin (Figure 11).

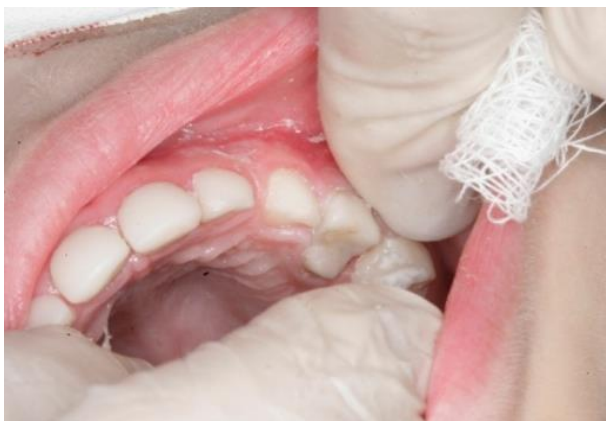

Figure 10. View of the upper left region after completion of endodontics, restorations and sealant application.

In element 84 there was a need for indirect pulp capping with calcium hydroxide cement (Dycal®), use of VIC as a backing material and restoration in composite resin in occlusal and distal and application of sealant.

In the 85-pulp cap element with Dycal® IVC lining and restoration in composite resin in the occlusal and vestibular (Figure 12).

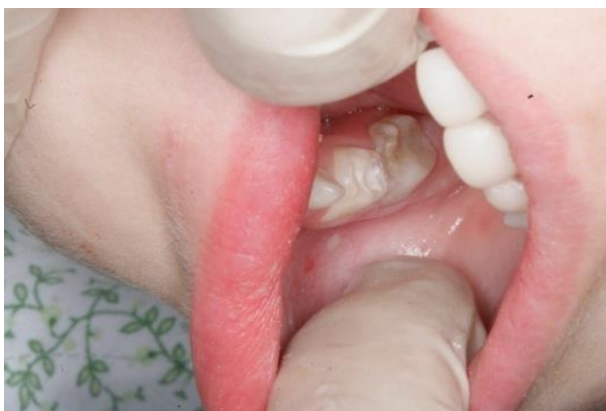

Figure 11. View of the lower left after completion of restorations.

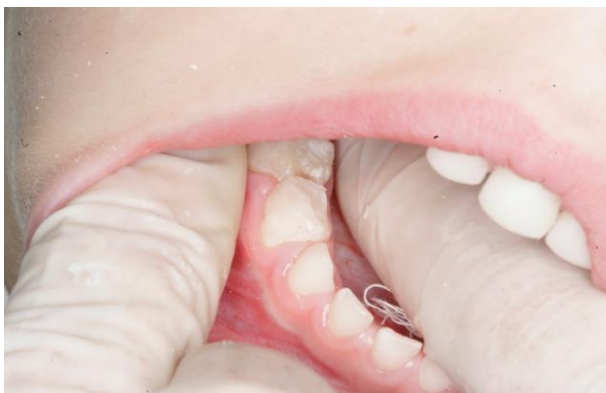

Figure 12. Side view of the lower right region.

Faced with a dentistry dental treatment made difficult by the patient's non-cooperation and after the attempt of all the management techniques, we can have pharmacological techniques for the control of anxiety and the cooperation of the child, to obtain a good clinical result in the short term. Therefore, it is up to the dental surgeon to analyze which behavior to take through a non-collaborative child, presenting and deciding with the parents what the sedative behavior to be chosen.

4. CONCLUSION

Sedation techniques, when well indicated and employed, have a high acceptance rate due to the good clinical outcome and the maintenance of the physical and psychological integrity of the child.

REFERENCES

- [01] Mallamed ST. Pain and anxiety control in Dentistry. *Oral Health* 1996 Feb; 86 (2): 11-16.
- [02] Góes MPS, Domingues MC, Couto GBL, Barreira AK. Ansiedade, medo e sinais vitais dos pacientes infantis. *Odontol. clín.-cient* (2010): 39-44.
- [03] Cogo K, Bergamaschi CC, Yatsuda R, Volpato MC, Andrade ED. Sedação consciente com benzodiazepínicos em odontologia. *Odontologia da Universidade Cidade de São Paulo* 2006; 18(2): 181-8.
- [04] Seger L. *Psicologia e odontologia uma abordagem integradora*. 4ª ed. São Paulo: Santos; 1998.
- [05] Teixeira TF, Quesada GAT. Terapia ansiolítica para pacientes odontológicos. *Saúde (Santa Maria)* 2004; 30(2): 100-103.
- [06] Moraes ABA, Sanchez KAS, Possobon RF, Costa Junior AL. *Psicologia e odontopediatria: A contribuição da análise funcional do comportamento*. *Psicologia* 2004; 17(1): 75-82.
- [07] Josgrilberg EB, Cordeiro RCL. Aspectos psicológicos do paciente infantil no atendimento de urgência. *Odontologia Clínica Científica*. Recife 2005; 4(1): 13-18.
- [08] Cogo K, Bergamaschi CC, Yatsuda R, Volpato MC, Andrade ED. Sedação consciente com benzodiazepínicos em odontologia. *Odontologia da Universidade Cidade de São Paulo* 2006; 18(2): 181-8.
- [09] Ferreira JMS, Aragão AKR, Colares V. Técnicas de controle do comportamento do paciente infantil: revisão de literatura. *Pesqui Bras Odontopediatria Clín Integr* 2009; 9(1): 247-251.
- [10] Guedes-Pinto AC, Bönecker M, Rodrigues CRMD. *Odontopediatria - Fundamentos em Odontologia*. São Paulo: Santos-GEN 2009; 9(1): 301-328.
- [11] Oliveira ACB, Pordeus IA, Paiva SM. O uso do óxido nítrico como uma opção no controle de comportamento em odontopediatria. *J Bras Odontopediatr Odontol Bebê* 2003; 6(32): 344-50.
- [12] McDonald RE, Avery DR, Dean JA. *Odontopediatria para crianças e adolescentes*. Rio de Janeiro: Elsevier 2011.
- [13] Neta C *et al.* O uso de óxido nítrico/oxigênio na clínica odontológica. Pernambuco 2014 [Trabalho de Conclusão de Curso], [acesso em 11 de Agosto de 2016] Disponível

em:>

<http://dspace.bc.uepb.edu.br/jspui/bitstream/123456789/4209/1/PDF%20-%20Maria%20Catarina%20da%20Costa%20Neta.pdf><

- [14] nome dos autores. Saúde Bucal: Odontopediatria para crianças e adolescentes. Conselho Federal de Odontologia 2014. [acesso 11 de março de 2016] Disponível em: <http://cfo.org.br/>
- [15] Brasil. Resolução do Conselho Federal de Odontologia – CFO 51/04 [acesso 23 de maio de 2016] Disponível em: http://www.portalmédico.org.br/resolucoes/CFM/2003/1670_2003.htm
- [16] McDonald RE, Avery DR, Dean JA, Odontopediatria para crianças e adolescentes. Rio de Janeiro. Elsevier 2011.
- [17] Benseñor FEM & Cicarelli DD. Sedação e Analgesia em terapia intensiva. Rev Bras Anesthesiol 2003; 53(5): 680 – 693.
- [19] Brunton LL, Bruce AC, Björn CK. As Bases Farmacológicas da Terapêutica de Goodman & Gilman-12. AMGH 2012; 3(1): 63-72.
- [20] Mello MAO, Silva YP. Sedação e analgesia em pronto atendimento pediátrico. Rev Med Minas Gerais 2010; 20(4): 37- 46.
- [21] Silva YP, Silva JF, Costa LP, Medeiros MF, Mota JAC. Sedação e Analgesia em pronto atendimento pediátrico: Artigo de Revisão. Revista de Medicina de Minas Gerais 2005; 15(2): 105-110.